



Arthroplasty in patients with rare conditions

## Drug-Induced Thrombocytopenia Secondary to Commonly Used Antibiotics in Total Joint Arthroplasty

Ian Savage-Elliott, MD, Victor J. Wu, MD<sup>\*</sup>, Fernando L. Sanchez, MD

Department of Orthopaedic Surgery, Tulane University School of Medicine, New Orleans, LA, USA

## ARTICLE INFO

## Article history:

Received 18 July 2019

Received in revised form

5 March 2020

Accepted 8 March 2020

Available online 22 April 2020

## Keywords:

Vancomycin

Rifampin

Platelet

Thrombocytopenia

Arthroplasty

Antibiotic

## ABSTRACT

Drug-induced thrombocytopenia secondary to antibiotic exposure is a rare complication more commonly associated with other medications. In this review, we present a case of antibiotic-induced thrombocytopenia and discuss the clinical picture and approach to identifying the complication. With increasing use of antibiotics that may be associated with drug-induced thrombocytopenia in perioperative prophylaxis protocols, surgeons need to be cognizant of this cause of thrombocytopenia in the postoperative patient. A delay in recognition and discontinuation of the offending agent can result in significant complications secondary to bleeding and superfluous testing.

© 2020 The Authors. Published by Elsevier Inc. on behalf of The American Association of Hip and Knee Surgeons. This is an open access article under the CC BY-NC-ND license (<http://creativecommons.org/licenses/by-nc-nd/4.0/>).

## Introduction

Drug-induced thrombocytopenia (DITP) is an adverse reaction that has been reported with more than 300 medications, most commonly due to drug-dependent platelet antibodies that produce a response from the reticuloendothelial system [1,2]. Previous research has shown that DITP is an underrecognized clinical problem that can lead to severe bleeding complications [3].

DITP is commonly associated with heparin but can be caused by antibiotics commonly used in primary total joint arthroplasty such as  $\beta$ -lactams and vancomycin. [4,5]. Other antibiotics associated with DITP, such as linezolid and rifampin, may be used as adjuncts in revision cases for suspected methicillin-resistant *Staphylococcus aureus* infections [6,7].

Although testing for antibiotic-induced antiplatelet antibodies remains the gold standard in diagnosis of DITP, such assays are costly and may not be commonly available. Therefore, a surgeon's suspicion of this complication in a patient with bleeding and/or thrombocytopenia is paramount to minimizing morbidity after orthopaedic procedures. With the increased use of vancomycin and other DITP-associated antibiotics in various forms as routine perioperative

prophylaxis protocols in primary total joint arthroplasty, early diagnosis is critical to avoid severe or nonsevere bleeding, reported at rates of 6% and 67%, respectively [8], as well as unnecessary tests.

## Case history

A 70-year-old man presented for revision of a failed left total knee arthroplasty secondary to global instability. Preoperative erythrocyte sedimentation rate, C-reactive protein, and white blood cell count had been within normal limits. His past medical history included chronic atrial fibrillation, hypertension, and embolic stroke. At the time of admission, his medications included amiodarone and apixaban for anticoagulation.

His operative course for revision knee arthroplasty was uneventful. He was given 1 gram (g) of vancomycin and 400 milligrams (mg) intravenous (IV) ciprofloxacin for prophylaxis. Ciprofloxacin was given because of his history of benign prostatic hyperplasia and recurrent urinary tract infections. In addition, he received 50,000 units of irrigation bacitracin via 3 L of 0.9% normal saline intraoperatively. Four intraoperative cultures were taken and sent for analysis. Postoperatively, he developed a bundle branch block on the cardiac monitor in the postanesthesia care unit. However, a coronary arteriogram revealed that he had clean coronary arteries and normal left ventricular function.

Surgical pathology did not find evidence of acute inflammation. However, 2 cultures grew *Staphylococcus aureus* in liquid media,

<sup>\*</sup> Corresponding author. Department of Orthopedic Surgery, Tulane University School of Medicine, 1430 Tulane Avenue, New Orleans, LA 70112, USA. Tel.: +1 504 988 3516.

E-mail address: [vwu1@tulane.edu](mailto:vwu1@tulane.edu)

and the patient was subsequently placed on a 6-week course of vancomycin and ciprofloxacin pending sensitivities. This treatment paradigm was consistent with a class 1 Tsukayama infection given the multiple intraoperative cultures positive on liquid media [9]. On postoperative day (POD)4, the cultures resulted with a methicillin-resistant *Staphylococcus aureus* periprosthetic infection, and the patient was started on a 6-week course of vancomycin and rifampin. The patient was discharged on POD5 on IV vancomycin 1 g every 12 hours and oral rifampin 300 mg every 8 hours. His platelet count at discharge was  $188 \times 10^3/\text{mm}^3$ .

On POD18, the patient was brought to the emergency department complaining of a syncopal episode at home. His systolic blood pressure was 70 mmHg in the field and improved with a bolus of 0.9% saline. There were no physical signs or evidence of a cerebrovascular event on imaging. An electrocardiogram demonstrated normal sinus rhythm with a right bundle branch block. Troponin was slightly elevated at 0.07 ng/mL (normal: 0.00–0.04 ng/mL) in the setting of mild renal disease (Cr 1.30, normal: 0.64–1.27). He was slightly anemic with a red blood cell count of  $3.46 \times 10^6/\text{mm}^3$  (normal:  $4.30\text{--}5.90 \times 10^6/\text{mm}^3$ ) and a hemoglobin of 10.9 g/dL (normal: 13.0–18.0 g/dL). White blood cell counts were slightly elevated to  $11.7 \times 10^3/\text{mm}^3$  (normal:  $4.5\text{--}11.0 \times 10^3/\text{mm}^3$ ) with 69.6% neutrophils (normal: 52.0–87.0). Coagulation laboratory results revealed a prothrombin time of 12.0 seconds (normal: 9.8–11.7 seconds), international normalized ratio of 1.2, and activated partial thromboplastin time of 23.0 seconds (normal: 21.0–32.0). Fibrinogen laboratory tests were not drawn. Consultation with cardiology confirmed that the syncopal episode was likely secondary to orthostatic hypotension. Therefore, the patient's hypertension medication was discontinued in addition to his apixaban and heparin.

An incidental finding on complete blood count labs was a platelet count of  $29 \times 10^3/\text{mm}^3$  (normal:  $140\text{--}440 \times 10^3/\text{mm}^3$ ). The patient had no petechia, ecchymosis, or peripheral lymphadenopathy. The differential diagnosis at the time was heparin-induced thrombocytopenia (HIT) secondary to heparin flushes of his peripherally inserted central catheter, disseminated intravascular coagulation, which was unlikely due to normal coagulation laboratory results, concurrent sepsis, or immune thrombocytopenic purpura. Hematology/oncology was consulted for the low platelet count, and we concluded that there was no indication for platelet transfusion and the patient's thrombocytopenia was secondary to therapeutic use of antibiotics. At this time (POD 20), the patient's platelet count had reached a nadir of  $20 \times 10^3/\text{mm}^3$ . His vancomycin and rifampin were subsequently switched to IV daptomycin, and his platelet count began to rise to  $31 \times 10^3/\text{mm}^3$  on POD 20. He was discharged home on oral linezolid with a platelet count of  $138,000 \times 10^3/\text{mm}^3$ . His hospital course was complicated by a deep vein thrombosis in his right arm provoked by a peripherally inserted central catheter after heparin was discontinued which warranted an inferior vena cava filter that was placed the following day.

## Discussion

Thrombocytopenia can be defined as a platelet level lower than  $100 \times 10^3/\text{mm}^3$  with a wide clinical presentation. Patients can be asymptomatic or present with petechial hemorrhages, oozing from the buccal mucosa or severe bleeding, with the most severe symptoms typically seen with platelet levels lower than  $20 \times 10^3/\text{mm}^3$  [10]. Although there is a lack of a standard definition, clinically significant thrombocytopenia has been defined as platelet counts dropping at least 50% of the baseline [11].

The causes of thrombocytopenia can be classified into problems with platelet production or increased platelet destruction. Many drugs cause a transient thrombocytopenia owing to myelosuppression or other mechanisms. The presentation of DITP is more clinically significant, with platelet counts usually dropping less

than  $20 \times 10^3/\text{mm}^3$  [3]. Like most immune adaptive responses, DITP follows a typical temporal pattern. It presents 5 to 10 days after the first exposure and then within hours of a second exposure.

The difficulty with diagnosis of DITP is the lack of a reliable standardized laboratory test [4]. While immunoassays for IgG or IgM antibodies do exist for some antibiotics [10], these tests may not be readily available to most providers. In addition, the tests require a prolonged period of treatment and may produce false negatives when DITP is recognized early in its course [12,13]. Because a delay in recognition can lead to significant morbidity and mortality, clinical criteria such as the Naranjo Adverse Drug Reaction Probability Scale [14] can help determine the probability of DITP.

The best course of treatment is discontinuation of the causative agent. Platelet transfusion is not indicated owing to continued immune destruction of the platelets in the presence of the offending agent [3]. However, transfusion can be considered in cases of severe bleeding and platelet counts less than  $20 \times 10^3/\text{mm}^3$  [2] and can be effective when performed after discontinuation of the causative agent [15].

Vancomycin-induced thrombocytopenia (VIT) and/or rifampicin-induced thrombocytopenia is much more scarcely reported in the literature. Of the 2, vancomycin is more commonly used in antibiotic prophylaxis, and therefore, the bulk of the literature addresses complications related to this antibiotic's usage. Hematopoietic complications of vancomycin range from roughly 2% to 12% [16]. However, the rate of VIT has not been accurately reported, and its incidence remains undetermined [17]. While VIT has been identified in other procedures [13,18], only 1 case report to our knowledge has been reported in the orthopaedic literature that involved vancomycin-impregnated cement after revision total knee arthroplasty [19]. In the all mentioned case reports, thrombocytopenia resolved upon withdrawal of vancomycin, and no further complication was reported. There is no gold standard regarding testing for VIT currently; however, the standard antibiotic-induced immune thrombocytopenia (AIT) clinical and laboratory criteria are generally recommended for suspected cases. Management has typically consisted of discontinuation of the causative medication, with transfusion being the next most commonly used treatment in the case of severe bleeding and some studies estimating transfusion rates as high as 2 of 3 patients [2]. Other treatments including corticosteroids, immunoglobulins, and plasma exchange have been used; however, none of these were clinically superior in a large retrospective series of 30 patients with VIT [10].

In the present case, the patient's platelet count met the criteria of decreasing  $\geq 50\%$  of the baseline by dropping from  $188 \times 10^3/$

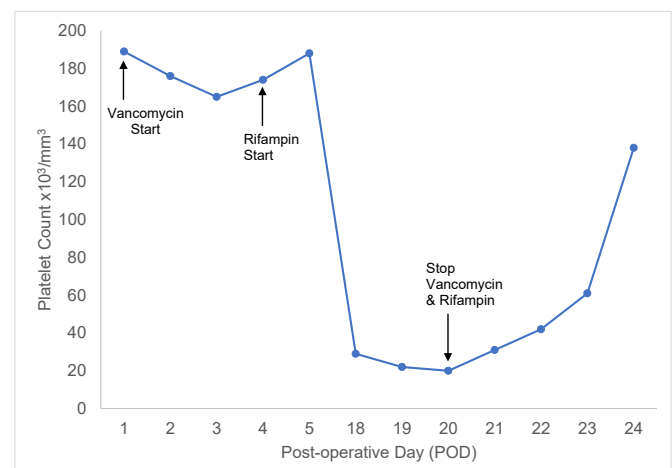


Figure 1. Response of platelet count to antibiotic therapy.

**Table 1**  
Naranjo scale for likelihood of adverse drug reaction (ADR).

Naranjo scale <sup>a</sup>	Yes	No	Score (vancomycin)	Score (rifampin)	Score (antibiotic <sup>b</sup> )
1. Are there previous conclusive reports of this reaction?	+1	0	0	0	0
2. Did the adverse event appear after the suspected drug was administered?	+2	-1	+2	+2	+2
3. Did the adverse reaction improve when the drug was discontinued or a specific antagonist was administered?	+1	0	+1	+1	+1
4. Did the adverse reaction reappear when the drug was readministered?	+2	-1	0	0	0
5. Are there alternative causes (other than the drug) that could on their own, have caused the reaction?	-1	+2	-1	-1	+2
6. Did the reaction reappear when a placebo was given?	-1	+2	0	0	0
7. Was the drug detected in the blood (or other fluids) in toxic concentrations?	+1	0	0	0	0
8. Was the reaction more severe when the dose was increased or less severe when the dose was decreased?	+1	0	0	0	0
9. Did the patient have a similar reaction to the same or similar drugs in any previous exposure?	+1	0	0	0	0
10. Was the adverse event confirmed by any objective evidence?	+1	0	0	0	0
Total:			2 (Possible)	2 (Possible)	5 (Probable)
• $\geq 9$ = Definite ADR					
• 5-8 = Probable ADR					
• 1-4 = Possible ADR					
• 0 = Doubtful ADR					

<sup>a</sup> 0 Points were given if the answer to the question was “do not know” or “not done.”

<sup>b</sup> Antibiotic refers to whether the adverse drug reaction was due to either vancomycin or rifampin compared with heparin.

mm<sup>3</sup> at discharge (POD5) to  $29 \times 10^3/\text{mm}^3$  at presentation (POD18). In contrast with previously published orthopaedic case reports, our patient did not display any outward symptoms of AIT, such as visible bleeding or petechial hemorrhages, and his thrombocytopenia was discovered incidentally while working up a syncopal episode. The main differential diagnoses included heparin-induced thrombocytopenia (HIT) and antibiotic-induced immune thrombocytopenia (AIT). Other possible causes of thrombocytopenia such as sepsis, disseminated intravascular coagulation, and immune thrombocytopenic purpura were less likely considering the clinical presentation and other laboratory values. Because DITP occurs within hours of a second exposure, HIT was less likely due to the patient's exposure to heparin in prior surgeries. The patient had not previously been exposed to vancomycin or rifampin, so the time course fit the 5-10 days that lead to an adverse reaction after a primary exposure. Immediately on switching antibiotics, the patient's platelet count began to recover (Fig. 1). Because both vancomycin and rifampin were stopped at the same time, the Naranjo Adverse Drug Reaction Probability Scale [14] indicated a “possible” adverse drug reaction when considering them individually. However, the scale indicated that these antibiotics were a “probably” cause of the thrombocytopenia when considered together against heparin (Table 1). This was later confirmed by negative antiheparin antibodies.

#### Current controversies and future considerations

Currently, the incidence of DITP has been reported as roughly 10 cases per 1 million patients [2]. While surgical prophylaxis for other surgeries appears to have significant precedent, the severity of and devastating consequences from infection in arthroplasty have led to continued debate regarding the selection, duration, and type of antibiotics used prophylactically. This controversy has continued even in the wake of recent consensus statements working to solve these issues. [20]

One of the most important future considerations surrounding AIT is the advancement and cost-effectiveness of wide-scale antibody testing. Recent studies have focused on routine testing for drug-dependent platelet antibodies; however, this is a costly endeavor with a lack of standardization and/or validation across multiple agents tested [21]. Furthermore, retrospectively isolating a specific causative agent of thrombocytopenia and bleeding is difficult, as often multiple possible offenders are discontinued at

the same point in time, leading to an unclear explanation of the cause of thrombocytopenia. [21] Currently, the Naranjo Adverse Drug Reaction Probability Scale remains an excellent starting point when clinical suspicion of a drug-induced hematopoietic complication is suspected. Further consideration of the cost-effectiveness of more routine specific platelet antibody testing is warranted. On the one hand, early diagnosis leads to avoidance of unnecessary treatments and discontinuation of the antibiotic, avoiding potential bleeding complications. On the other hand, antibody testing is a costly endeavor and should not become a routine laboratory study used in patients postoperatively. Determining the appropriate clinical scenario is a matter of clinical acumen and experience.

#### Summary

Antibiotic-induced immune thrombocytopenia (AIT) is a rare postoperative complication that can develop after the use of commonly used antibiotics in total joint arthroplasty. The use of temporal information and clinical criteria such as the Naranjo Adverse Drug Reaction Probability Scale can help providers promptly identify the issue and withdraw the offending agent. Because the diagnosis of drug-induced thrombocytopenia (DITP) is often overlooked in the presence of other potential causes of thrombocytopenia, providers should remain wary of AIT in the postoperative patient treated with antibiotics.

#### KEY POINTS

1. Consider an adverse reaction to antibiotics when more common causes of thrombocytopenia such as heparin-induced thrombocytopenia, disseminated intravascular coagulation, and sepsis are low on your differential.
2. Temporal information and the Naranjo scale can help pinpoint the offending agent when laboratory tests are unavailable. A primary exposure may not have a reaction for up to 5-10 days. A secondary exposure will lead to thrombocytopenia within hours. Remember to consider that the patient's primary exposure in that case may have been silent.
3. Withdrawal of the offending agent is sufficient for treatment. Consider platelet transfusion in cases of severe bleeding and platelet count less than  $20 \times 10^3/\text{mm}^3$  after removal of the offending agent.

## Conflict of interest

Fernando L. Sanchez, MD, lists the following relevant financial activities outside of this work and/or other relationships or activities that readers could perceive to have influenced, or that give the appearance of potentially influencing this manuscript: grants and other from Medacta, grants and other from DJO.

For full disclosure statements refer to <https://doi.org/10.1016/j.artd.2020.03.006>

## References

- [1] Loo AS, Gerzenshtein L, Ison MG. Antimicrobial drug-induced thrombocytopenia: a review of the literature. *Semin Thromb Hemost* 2012;38(8):818.
- [2] Mohammadi M, Jahangard-Rafsanjani Z, Sarayani A, Hadjibabaei M, Taghizadeh-Ghehi M. Vancomycin-induced thrombocytopenia: a narrative review. *Drug Saf* 2017;40(1):49.
- [3] Arnold DM, Nazi I, Warkentin TE, et al. Approach to the diagnosis and management of drug-induced immune thrombocytopenia. *Transfus Med Rev* 2013;27(3):137.
- [4] Arnold DM, Kukaswadia S, Nazi I, et al. A systematic evaluation of laboratory testing for drug-induced immune thrombocytopenia. *J Thromb Haemost* 2013;11(1):169.
- [5] Cuker A. Heparin-induced thrombocytopenia (HIT) in 2011: an epidemic of overdiagnosis. *Thromb Haemost* 2011;106(6):993.
- [6] Osmon DR, Berbari EF, Berendt AR, et al. Diagnosis and management of prosthetic joint infection: clinical practice guidelines by the Infectious Diseases Society of America. *Clin Infect Dis* 2013;56(1):e1.
- [7] Baldoni D, Haschke M, Rajacic Z, Zimmerli W, Trampuz A. Linezolid alone or combined with rifampin against methicillin-resistant *Staphylococcus aureus* in experimental foreign-body infection. *Antimicrob Agents Chemother* 2009;53(3):1142.
- [8] Kenney B, Stack G. Drug-induced thrombocytopenia. *Arch Pathol Lab Med* 2009;133(2):309.
- [9] Tsukayama DT, Estrada R, Gustilo RB. Infection after total hip arthroplasty. A study of the treatment of one hundred and six infections. *J Bone Joint Surg Am* 1996;78(4):512.
- [10] Von Drygalski A, Curtis BR, Bougie DW, et al. Vancomycin-induced immune thrombocytopenia. *N Engl J Med* 2007;356(9):904.
- [11] Wang TY, Ou FS, Roe MT, et al. Incidence and prognostic significance of thrombocytopenia developed during acute coronary syndrome in contemporary clinical practice. *Circulation* 2009;119(18):2454.
- [12] Kuruppu JC, Le TP, Tuazon CU. Vancomycin-associated thrombocytopenia: case report and review of the literature. *Am J Hematol* 1999;60(3):249.
- [13] Danieletto CF, Ferreira GZ, Farah GJ, Cuman RK. Vancomycin-induced thrombocytopenia: a rare adverse effect in a patient -submitted to bone graft in the jaw. *Spec Care Dentist* 2017;37(1):38.
- [14] Naranjo CA, Busto U, Sellers EM, et al. A method for estimating the probability of adverse drug reactions. *Clin Pharmacol Ther* 1981;30(2):239.
- [15] Yamanouchi J, Hato T, Shiraishi S, Takeuchi K, Yakushijin Y, Yasukawa M. Vancomycin-induced immune thrombocytopenia proven by the detection of vancomycin-dependent anti-platelet antibody with flow cytometry. *Intern Med* 2016;55(20):3035.
- [16] Black E, Lau TT, Ensom MH. Vancomycin-induced neutropenia: is it dose- or duration-related? *Ann Pharmacother* 2011;45(5):629.
- [17] Ganly P, Downing J, Stiven P, Frizelle F, Badami K. Clinical and serological diagnoses of a patient with vancomycin-induced thrombocytopenia. *Transfus Med* 2011;21(2):137.
- [18] Gerstein W, Colombo E, Harji F. Documented vancomycin-induced severe immune-mediated thrombocytopenia. *BMJ Case Rep* 2018;2018:1–4.
- [19] O'Donnell E, Shepherd C, Neff A. Immune thrombocytopenia from vancomycin in orthopedic cement. *Am J Hematol* 2007;82(12):1122.
- [20] Aboltins CA, Berdal JE, Casas F, et al. Hip and knee section, prevention, antimicrobials (systemic): proceedings of International consensus on orthopedic infections. *J Arthroplasty* 2019;34(2s):S279.
- [21] Aster RH, Curtis BR, McFarland JG, Bougie DW. Drug-induced immune thrombocytopenia: pathogenesis, diagnosis, and management. *J Thromb Haemost* 2009;7(6):911.