



Arthroplasty in patients with rare conditions

Bilateral Posterior-Stabilized Total Knee Arthroplasty in a Patient With Osteopetrosis and Literature Review

David Beaton Comulada, MD^a, Lenny Rivera, MD^{a, *}, Gabriel Echegaray, MD^a, Roberto Colón, MD^a, Samuel Rodríguez-Santiago, MS^b, Antonio Otero, MD^a

^a Department of Orthopaedic Surgery, University of Puerto Rico Medical Sciences Campus, San Juan, PR, USA

^b School of Medicine, University of Puerto Rico Medical Sciences Campus, San Juan, PR, USA

ARTICLE INFO

Article history:

Received 22 May 2020

Received in revised form

10 August 2020

Accepted 29 September 2020

Available online 1 November 2020

Keywords:

Osteopetrosis

Osteoclast

Osteoarthritis

Arthroplasty

Periprosthetic fracture

ABSTRACT

We present a case report of a patient with osteopetrosis and refractory bilateral knees osteoarthritis who underwent bilateral total knee arthroplasties (TKAs). After conservative management has failed, surgical treatment with arthroplasty is an excellent alternative with satisfactory outcomes. TKA in patients with osteopetrosis has only been described in 6 other case studies, none of which underwent bilateral TKA. To perform this procedure, additional attention should be directed toward the presurgical planning because of the amplified difficulty of the procedure and the altered bone biology that increases the risks of intraoperative fractures and markedly extends the time of surgery. This report describes a case of osteopetrosis with refractory osteoarthritis managed with bilateral TKA, the surgical technique and special considerations, complications, and future recommendations.

Published by Elsevier Inc. on behalf of The American Association of Hip and Knee Surgeons. This is an open access article under the CC BY-NC-ND license (<http://creativecommons.org/licenses/by-nc-nd/4.0/>).

Introduction

First described as “marble bone disease” in 1904 by the German radiologist Albert Schönberg, osteopetrosis is a rare inheritable metabolic bone disease that encloses a wide spectrum of osteoclastic activity dysfunction that leads to excessive bone mineral density [1]. Osteoclast dysfunction stems from a defect in the bone resorption process: differentiation from hematopoietic stem cells, polarization, cell-surface binding, demineralization, and matrix degradation [2]. A defect in any of these stages results in either normal to increased numbers of osteoclasts (osteoclastic-rich form) or in poor to absent osteoclasts (osteoclastic-poor form) [3,4]. Three major groups have been developed based on the type of inheritance, onset, severity, and secondary clinical manifestations: autosomal recessive infantile malignant osteopetrosis, autosomal recessive intermediate mild osteopetrosis, and autosomal dominant adult-onset benign osteopetrosis [5–7]. The incidence varies from 1:200,000 for autosomal recessive osteopetrosis and 1:20,000 for autosomal dominant osteopetrosis [8,9]. Irrespective of the type

of osteopetrosis, it is usually diagnosed based on pathognomonic radiographic features found on a skeletal survey [1,10].

Owing to the natural history of this condition that varies from limited clinical abnormalities to a complex prevalence of multiple orthopaedic disorders, its management represents a challenge for the orthopaedic surgeon [1,2,11], particularly in joint replacement surgery, where the nature of the brittle bone and narrow medullary canal increases the risk of intraoperative fractures and bone necrosis and difficulty in achieving proper alignment to make the desired bone cuts. Furthermore, no definitive curative treatment is currently available. Patients may have a history of coxa vara, frequent fractures, malunion, nonunion, or osteomyelitis, predisposing them to early-onset osteoarthritis (OA) [1,11,12]. Initial management essentially consists of symptomatic treatment of complications, later accompanied with medical treatment of calcitriol and bisphosphonate therapy. Severe disease usually involves surgical management with open reduction and internal fixation or with total joint arthroplasty and requires an increased awareness of possible complications and unexpected outcomes [12–15]. Few reports have been written about these patients undergoing total knee arthroplasty (TKA). We therefore would like to present a case of a patient with osteopetrosis who underwent staged bilateral TKA and a detailed literature review.

* Corresponding author. Universidad de Puerto Rico Recinto de Ciencias Medicas, Paseo Dr. Jose Celso Barbosa, PO Box 365067, San Juan, PR 00936-5067, USA. Tel.: +1 787 951 2597.

E-mail address: lenny.rivera@upr.edu

KEY POINTS

- The skeletal deformities, previous fractures, and compression of the articular cartilage seen in patients with osteopetrosis may lead to early-onset osteoarthritis.
- Patients with refractory knee osteoarthritis benefit from total knee arthroplasty, which has demonstrated satisfactory outcomes.
- It is imperative to understand bone biology because patients with osteopetrosis have an increased bone density, a narrow to absent medullary canal, and poor bone supply.
- Total knee arthroplasty in these patients is a technically demanding procedure that requires a detailed presurgical plan and increased awareness of surgical time, intraoperative fractures, and infections.

Case history*Preoperative evaluation*

A 64-year-old Hispanic man with an already established diagnosis of osteopetrosis, exhibiting no symptoms or manifestations of the disease, presented to the clinic with a chief complaint of bilateral knee pain; left knee pain was greater than that of the right knee. The patient referred several years of progressive limitation of activities without a previous history of trauma, infection, or other medical comorbidities. Trials of nonsurgical management

consisting of nonsteroidal anti-inflammatory drugs and steroid injections failed to relieve symptoms. Physical examination demonstrated bilateral knee swelling with diffuse tenderness and moderate effusion. Knee stability assessment revealed no increased laxity or instability of either knee. The coronal alignment of both knees was neutral, and their range of motion was 5–105 degrees. Neurovascular evaluations of both lower extremities were within normal limits. Standing anteroposterior and lateral knee radiographs revealed grade IV Kellgren-Lawrence OA of both knees (Fig. 1a and b); there was also evidence of extensive sclerosis within the femur, tibia, and fibula. Given the patient's clinical presentation and failed conservative management, TKA was recommended. After the risks and benefits of the procedure were explained to the patient, he consented for staged bilateral TKA.

Surgical technique

The left TKA was performed initially, followed by the right TKA 10 months later. Both surgeries were performed by the senior author using a tourniquet. The surgical time reported for the left TKA was 1 hour and 30 minutes, whereas for the right TKA, a surgical time of 1 hour and 23 minutes was reported. The TKA system used for the procedures was a posterior-stabilized Biomet Vanguard Knee System (Biomet, Warsaw, IN). The following is a description of the surgical technique and operative findings of the left TKA. Standard instrumentation was used, and preoperative radiographic templating was performed using standing short knee radiographs. The radiographs were used to determine the tibial coronal and distal femoral cuts. The tibial coronal cuts were based on 90 degrees neutral to the mechanical axis, and the distal femoral cuts were based at 5 degrees of valgus to the femur anatomical axis.

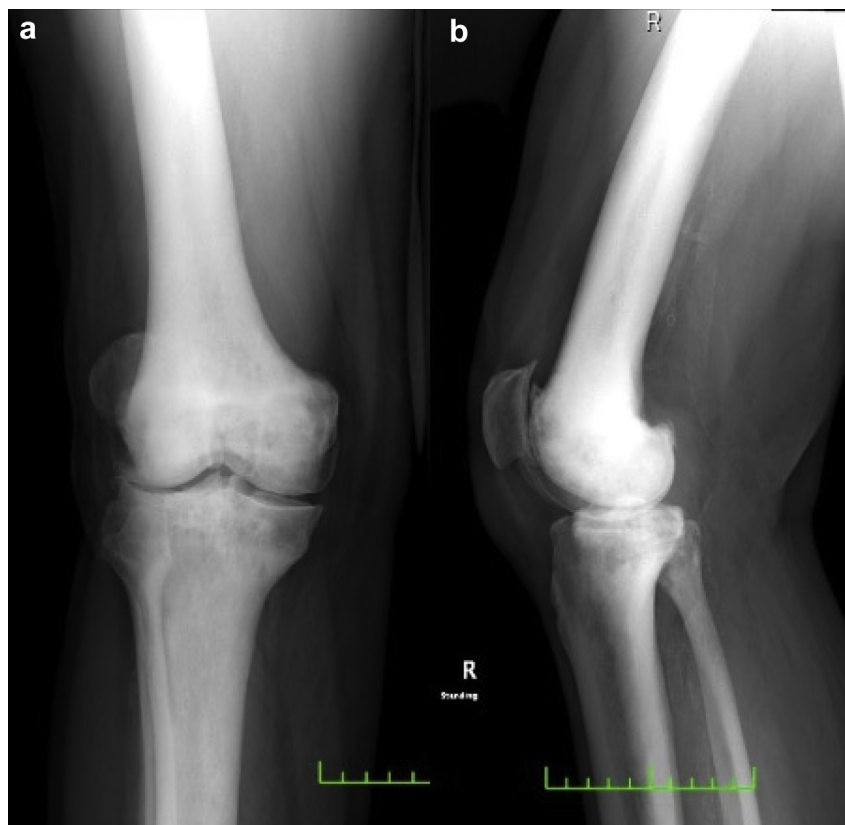


Figure 1. Preoperative radiographs of the right knee. AP (a) and lateral (b) views revealed severe osteoarthritic changes and extensive sclerotic changes of the femur, tibia, and fibula. AP, anteroposterior.

A standard medial parapatellar approach was made for the procedure. Extramedullary guides without the aid of fluoroscopy were used for distal femoral and proximal tibial cuts to prevent known complications of intramedullary guide placement. The proximal aspect of the medial parapatellar approach was extended to allow for more accurate and stable extramedullary guide placement of the femur. Femoral and tibial bone cuts were difficult and required 8 saw blades, copious irrigation, and 5 drill batteries. The medial distal femoral bone resection was measured before the cut was made to diminish the possibility of altered angles due to the limited fixation of the extramedullary guide. The posterior

condyle axis was used to establish femoral rotation. The knee did not present with a fixed deformity, and besides standard soft-tissue dissection for exposure, no formal releases were required to obtain symmetrical gaps. Posterior-stabilized knee design was used. The preparation of 'the box' of the femoral component required osteotome. A medial condyle fracture without cortical extension occurred. Fracture was stable, and no additional fixation was used. The tibial knee preparation included a reciprocating saw blade to mitigate standard central reaming. The patella was not resurfaced. The bony surfaces obtained before the final implants were highly sclerotic. Multiple 2.5-mm drill holes were made to optimize

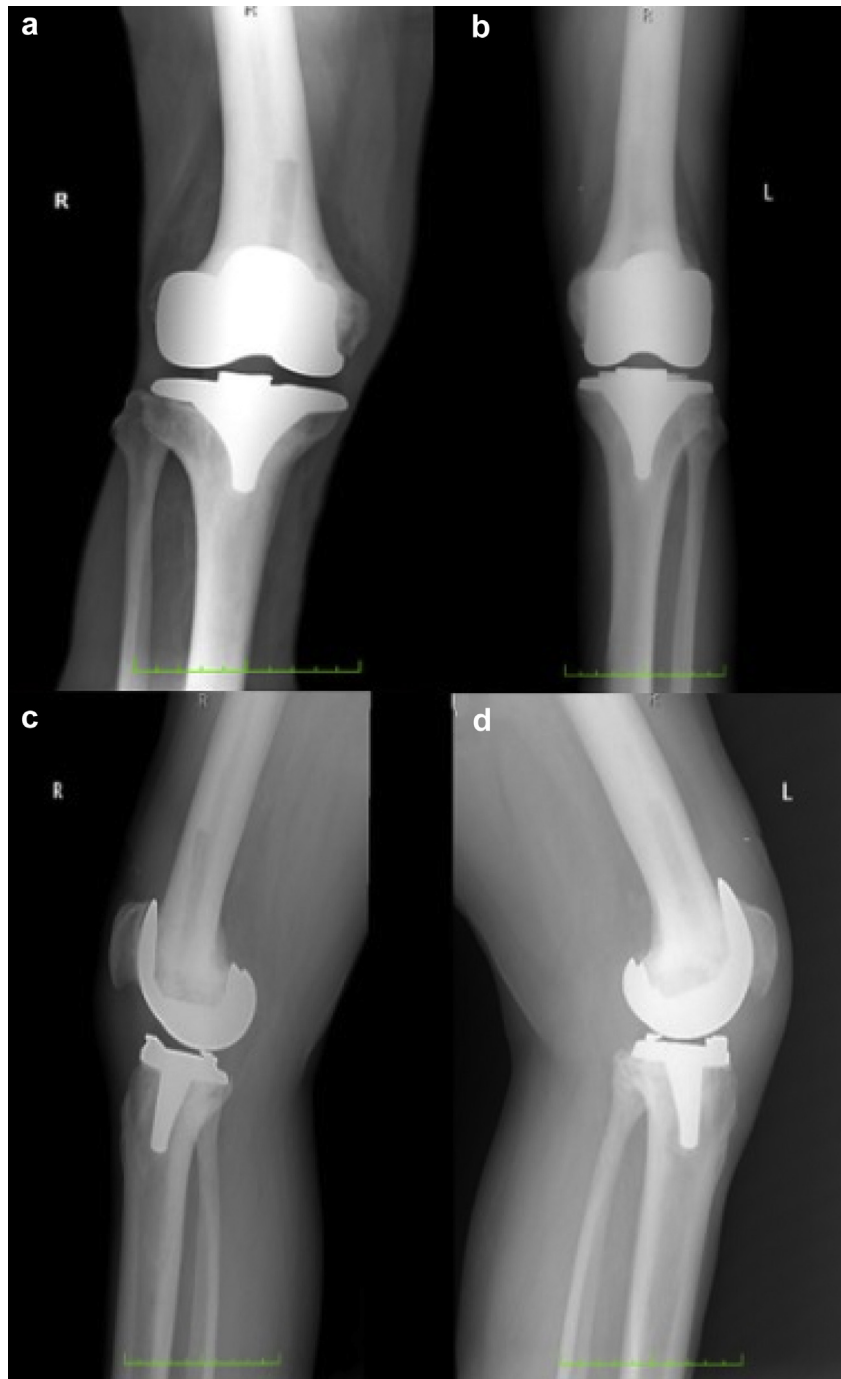


Figure 2. Postoperative bilateral AP (a and b) and lateral (c and d) radiographs revealing proper alignment of implants at 22 months of left TKA (b and d) and at 12 months of right TKA (a and c). AP, anteroposterior.

Table 1
Case studies of total knee arthroplasty in patients with osteopetrosis.

Author	Age (years)	Gender	Type of implant	Fixation	Complications	Surgical time	Follow-up period
Casden [23]	50	Female	Not specified	Cemented	None	NR	2 Years
Strickland [24]	68	Female	Not specified	Cemented	None	2 hours and 25 minutes	20 Years
Strickland [24]	42	Female	Posterior stabilized	Cemented	None	2 hours and 30 minutes	2 Years
Mayer [14]	58	Male	Patient-specific instrumentation, cruciate-retaining	Cemented	Medial condyle fracture	NR	6 Months
van Hove [25]	41	Female	Cruciate-retaining mobile bearing	Cementless	Iatrogenic tibia fracture	NR	1 Year
Xie [13]	59	Female	Posterior stabilized	Cemented	Medial epicondyle fracture fixed with plate	NR	15 Months

NR, not reported.

cement interdigitation. The final components were cemented in place. The medial condyle was in an anatomic reduction before implantation; for this reason, no recommendations in weight-bearing limitation or the use of a knee brace were provided. No instability in extension flexion or flexion was encountered. Full extension and 90 degrees of flexion were obtained before discharge to an inpatient rehabilitation facility with instructions for standard postoperative care with weight-bearing and range of motion as tolerated. The postoperative period was uneventful. No wound or infection complications occurred, and the patient demonstrated a steady clinical progression.

Postoperative evaluation

Postoperative follow-up radiographs of the 22-month left TKA and the 12-month right TKA demonstrated proper implant position with no signs of loosening (Fig. 2). The patient could ambulate freely without assistance and could perform his activities of daily living without difficulty. There was significant improvement on the patient's postoperative self-reported outcomes. The preoperative Knee Society Score was 43 on the left knee and 45 on the right knee, and the postoperative Knee Society Score was 83 on the left knee and 85 on the right knee. The preoperative Function Score was 55 for both knees, which gave a Total Knee Society Score of 98 and 100 on the left and right knees, respectively. The postoperative Function Scores were each 85, which gives a Total Knee Society Score of 168 and 170 on the left and right knees, respectively. The preoperative Western Ontario McMaster score for each knee was 25.8, and the Oxford Knee Score was 12. The postoperative Western Ontario McMaster score and Oxford Knee Score for both knees were 78 and 31, respectively.

Discussion

OA is a prevalent disorder in patients with osteopetrosis [16]. Skeletal deformities, previous fractures, and compression of the articular cartilage by the hard-subchondral bone seen in patients with osteopetrosis are associated with the early development of OA [17–19]. As it occurs with any typical patient with OA, most patients with osteopetrosis are initially managed conservatively with

nonoperative treatment. However, once conservative management fails, surgical management is warranted, particularly joint arthroplasty. In our case presentation, the patient underwent bilateral TKA successfully at 12-month follow-up. Nonetheless, these patients require special consideration when deciding to undergo surgical management because of their medical condition that affects their bone biology. One of these considerations is the theoretically increased risk of osteomyelitis in osteopetrosis cases [20–22]. The poor bone blood supply and relative osteopenia have been associated with an increased risk of osteomyelitis. Despite this increased risk of infection, our literature review of patients with osteopetrosis undergoing arthroplasty surgery did not reveal any case complicated by infection.

Patients with osteopetrosis have a narrow medullary canal or, in some instances, a completely missing medullary canal. This condition makes the surgery challenging because of the difficulty to prepare to ream the intramedullary canal and make the bone cuts. As such, it is crucial to have a good surgical plan. Surgeons should be aware that owing to the stiffness and increased density of the bone, an increased number of saw blades, batteries, and high-speed burrs must be obtained for the surgery. In our case, we used 8 saw blades and 5 batteries. Our literature review of other osteopetrosis TKA (Table 1) found that only Mayer et al. reported the exact amount of saw blades and batteries used in the surgery (4 saw blades and 9 batteries) [14]. In addition, the increase in heat generated when using drill bits may lead to broken drill bits and osteonecrosis. As such, we recommend low-speed drilling complemented with continuous cold saline to diminish the risk of bone thermal injury and necrosis. This presurgical planning may seem trivial at some institutions; nevertheless, not all institutions have a reasonable surgical budget or immediate available equipment. Thus, it is paramount to design a surgical plan that includes an additional amount of batteries and saw blades expected to be used during the surgery. Another technical aspect to consider during the surgery is the narrowness or absence of the medullary canal. Therefore, the use of an extramedullary guide is preferable, whereas the use of an intramedullary guide is not recommended. Mayer et al. reported the use of patient-specific implants with excellent results [14]. They argue that using patient-specific instrumentation eliminates intramedullary malalignment and

Table 2
Technical considerations when performing total knee arthroplasty in patients with osteopetrosis.

Surgical pearls
Technical considerations when performing TKA in patients with osteopetrosis
<ul style="list-style-type: none"> • Procure adequate amount of saw blades (4–8) and batteries (5–9) • Perform low-speed drilling with copious irrigation to decrease the risk of osteonecrosis • Plan to use extramedullary guide for TKA referencing • If performing a cemented TKA, consider performing multiple drill holes to increase cement interdigitation • Plan for an expected increase in the surgical time and an increased risk of intraoperative bone fracture • Consider the use of ultracongruent inserts and avoiding patellar resurfacing to decrease the risk of intraoperative bone fracture

minimizes drilling, reaming, and saw passes, making it an attractive option for TKA in patients with osteopetrosis. In addition, they state that it may decrease surgical time, although the surgical time in their case was not reported. Nonetheless, this type of implant may not be accessible to all patients because of financial cost or simply lack of availability. Regardless, the literature indicates that at short-term follow-up, good patient outcomes are appreciable with the use of standard equipment [13,24–26]. The surgical time of the TKA must always be considered, as increased surgical time in these patients is reported throughout the literature [24]. When we analyzed other cases of patients with osteopetrosis undergoing TKA, only Strickland and Berry reported the surgical time in each of their cases. The surgical time for both of their cases ranged from 2 hours and 25 minutes to 2 hours and 30 minutes. This is a vast increase compared with the approximated average surgical time of a primary TKA (1 hour) [27,28]. In our case, the left TKA surgical time was 1 hour and 30 minutes and the right TKA surgical time was 1 hour and 23 minutes, a significant increase from the average surgeon's surgical time when performing primary knee arthroplasties.

The increased density and stiffness of the bone makes it susceptible to iatrogenic fractures [18,20,21]. In our case, the left knee suffered a medial condyle fracture that was stable and did not require fixation. Of the 6 other cases that we found in our literature review of TKA in patients with osteopetrosis, half of them (3) reported intraoperative iatrogenic fractures [13,14,23–25]. Xie et al. reported a medial epicondyle fracture that was fixed with a spider plate and went to successful bony union [13]. Mayer et al. reported a medial condyle fracture that was stable and required no surgical fixation and underwent bony union (analogous to our case) [14]. Finally, van Hove et al. reported a tibial fissure fracture distal to the tibia cone that occurred during implant impaction [25]. It is noteworthy to highlight that in their case, they used a cementless implant. Although we are presenting a case report, not a prevalence study, it seems that half of the cases in the literature have suffered an intraoperative fracture. Thus, there is a greater risk of intraoperative fracture than that of a typical primary TKA, which has a reported prevalence of 0.39%–2.2% [29,30]. van Hove et al. also evaluated intraoperative fractures while comparing the different autosomal dominant osteopetrosis types. They referred to them as autosomal dominant osteopetrosis type 1 and autosomal dominant osteopetrosis type 2 patients. Based on molecular analysis, they stated that autosomal dominant osteopetrosis type 2 patients were at an increased risk of suffering intraoperative iatrogenic fractures because of impaired osteoclasts bone resorption when compared with normal osteoclastic function seen in autosomal dominant osteopetrosis type 1 patients [25]. However, this statement was based on the comparison of only 2 cases and it was not found to be clinically relevant.

Despite the increased risk of intraoperative fractures seen in patients with osteopetrosis, some technical considerations related to the patella and implant insert selection may be able to reduce it. The decision not to perform patellar resurfacing in either of our TKA was made in accordance to other case studies and surgeon's preference [13,14,23–25]. The rationale behind was based on contemplating the patient's increased bone stiffness and density that increases the risk of intraoperative fracture and the technical difficulty of the procedure. A posterior-stabilized implant was selected for our case based on the surgeon's preference. However, special consideration to implant selection could prove beneficial in these types of cases. The use of an implant that avoids the need of a cam-mechanism by means of a cruciate-retaining implant or an ultra-congruent insert may reduce the risk of condylar fracture and extensive bone resection associated with the preparation of an intercondylar box [31,32].

Another important aspect to consider in the surgery is the use of polymethyl methacrylate bone cement. Most cases of TKA in patients with osteopetrosis consisted of cemented arthroplasty, and only one case was performed with a cementless implant [25]. It is important to note that this cementless case did have good outcomes at 1-year follow-up. In cemented arthroplasty, it is recommended to perform multiple drill holes to the femur and tibia to increase the surface area of cement and interdigitation. This aids in securing the prosthesis in place.

Current controversies and future directions

Currently, there is no curative treatment for osteopetrosis. Most patients with osteopetrosis develop early-onset OA, requiring surgery in some refractory cases. Through good surgical planning (Table 2), a stable, well-aligned TKA and satisfactory patient outcomes can be obtained. The medical literature and studies regarding the use of specific arthroplasty surgical techniques such as navigation, patient-specific instrumentations, or the type of the implant used are scarce. Further studies in this area will aid in establishing appropriate surgical plans, implant selection, and how to manage intraoperative complications. In addition, there is a lack of studies evaluating the natural progression of the disease, and studies with a larger sample size and longer periods of follow-up will aid in the establishment of clear guidelines on the management of these patients, allowing better patient management and predictable surgical outcomes and complications.

Summary

Although osteopetrosis has no cure, TKA is an excellent surgical option for patients with osteopetrosis and advanced knee OA after conservative management has failed. The surgical literature consistently reveals improved patient outcomes after TKA. However, it is a technically demanding surgery and detailed presurgical planning is imperative because of an increased risk of fractures and an increased use of surgical equipment such as saw blades and batteries. In addition to the inherent technically demanding nature of the procedure, the time of surgery is markedly increased when compared with a TKA in a patient without osteopetrosis. No differences in outcomes have been able to be established based on the type of implants (cemented vs cementless). Owing to a theoretical risk of osteomyelitis, more studies are needed for the evaluation of the incidence of infections and complications in these patients.

Conflict of interests

The authors declare there are no potential conflicts of interest.

References

- [1] Wu CC, Econs MJ, DiMeglio LA, et al. Diagnosis and management of osteopetrosis: consensus guidelines from the osteopetrosis working group. *J Clin Endocrinol Metab* 2017;102(9):3111.
- [2] Del Fattore A, Cappariello A, Teti A. Genetics, pathogenesis and complications of osteopetrosis. *Bone* 2008;42(1):19.
- [3] Helfrich MH. Osteoclast diseases. *Microsc Res Tech* 2003;61(6):514.
- [4] Flanagan AM, Massey HM, Wilson C, Vellodi A, Horton MA, Steward CG. Macrophage colony-stimulating factor and receptor activator NF-kappaB ligand fail to rescue osteoclast-poor human malignant infantile osteopetrosis in vitro. *Bone* 2002;30(1):85.
- [5] Van Hul E, Gram J, Bollerslev J, et al. Localization of the gene causing autosomal dominant osteopetrosis type I to chromosome 11q12–13. *J Bone Miner Res* 2002;17(6):1111.
- [6] Stoker DJ. Osteopetrosis. *Semin Musculoskelet Radiol* 2002;6(4):299.
- [7] Whyte MP. Carbonic anhydrase II deficiency. *Clin Orthop Relat Res* 1993;294:52.
- [8] Bollerslev J, Andersen Jr PE. Radiological, biochemical and hereditary evidence of two types of autosomal dominant osteopetrosis. *Bone* 1988;9(1):7.

- [9] Johnston Jr CC, Lavy N, Lord T, Vellios F, Merritt AD, Deiss Jr WP. Osteopetrosis. A clinical, genetic, metabolic, and morphologic study of the dominantly inherited, benign form. *Medicine (Baltimore)* 1968;47(2):149.
- [10] Faden MA, Krakow D, Ezgu F, Rimoin DL, Lachman RS. The Erlenmeyer flask bone deformity in the skeletal dysplasias. *Am J Med Genet A* 2009;149A(6):1334.
- [11] Armstrong DG, Newfield JT, Gillespie R. Orthopedic management of osteopetrosis: results of a survey and review of the literature. *J Pediatr Orthop* 1999;19(1):122.
- [12] Landa J, Margolis N, Di Cesare P. Orthopaedic management of the patient with osteopetrosis. *J Am Acad Orthop Surg* 2007;15(11):654.
- [13] Xie L, Ding F, Jiao J, Kan W, Wang J. Total Hip and Knee arthroplasty in a patient with osteopetrosis: a case report and review of the literature. *BMC Musculoskelet Disord* 2015;16:259.
- [14] Mayer SW, Hug KT, Hansen BJ, Bolognesi MP. Total knee arthroplasty in osteopetrosis using patient-specific instrumentation. *J Arthroplasty* 2012;27(8):1580.e1.
- [15] Manzi G, Romanò D, Moneghini L, Romanò CL. Successful staged hip replacement in septic hip osteoarthritis in osteopetrosis: a case report. *BMC Musculoskelet Disord* 2012;13:50.
- [16] Cameron HU, Dewar FP. Degenerative osteoarthritis associated with osteopetrosis. *Clin Orthop Relat Res* 1977;127:148.
- [17] Girard J, Vendittoli PA, Lavigne M, Roy AG. Resurfacing arthroplasty of the hip in osteopetrosis. *J Bone Joint Surg Br* 2006;88(6):818.
- [18] de Palma L, Tulli A, Maccauro G, Sabetta SP, del Torto M. Fracture callus in osteopetrosis. *Clin Orthop Relat Res* 1994;308:85.
- [19] Bollerslev J, Mosekilde L. Autosomal dominant osteopetrosis. *Clin Orthop Relat Res* 1993;294:45.
- [20] Shapiro F. Osteopetrosis. Current clinical considerations. *Clin Orthop Relat Res* 1993;294:34.
- [21] Milgram JW, Jasty M. Osteopetrosis. A morphological study of twenty-one cases. *J Bone Joint Surg Am* 1982;64(6):912.
- [22] Agrawal A, Maniar A, Maniar R. Bilateral girdlestone procedure as a treatment modality in a case of complicated adult-onset osteopetrosis: a case report. *JBJS Case Connect* 2019;9(4):e0179.
- [23] Casden AM, Jaffe FF, Kastenbaum DM, Bonar SF. Osteoarthritis associated with osteopetrosis treated by total knee arthroplasty. Report of a case. *Clin Orthop Relat Res* 1989;247:202.
- [24] Strickland JP, Berry DJ. Total joint arthroplasty in patients with osteopetrosis: a report of 5 cases and review of the literature. *J Arthroplasty* 2005;20(6):815.
- [25] van Hove RP, de Jong T, Nolte PA. Autosomal dominant type I osteopetrosis is related with iatrogenic fractures in arthroplasty. *Clin Orthop Surg* 2014;6(4):484.
- [26] Janecki CJ, Nelson CL. Osteoarthritis associated with osteopetrosis treated by total hip replacement arthroplasty. Report of a case. *Cleve Clin Q* 1971;38(4):169.
- [27] Stronach BM, Pelt CE, Erickson J, Peters CL. Patient-specific total knee arthroplasty required frequent surgeon-directed changes. *Clin Orthop Relat Res* 2013;471(1):169.
- [28] Nunley RM, Ellison BS, Ruh EL, et al. Are patient-specific cutting blocks cost-effective for total knee arthroplasty? *Clin Orthop Relat Res* 2012;470(3):889.
- [29] Alden KJ, Duncan WH, Trousdale RT, Pagnano MW, Haidukewych GJ. Intraoperative fracture during primary total knee arthroplasty. *Clin Orthop Relat Res* 2010;468(1):90.
- [30] Pinaroli A, Piedade SR, Servien E, Neyret P. Intraoperative fractures and ligament tears during total knee arthroplasty. A 1795 postero stabilized TKA continuous series. *Orthop Traumatol Surg Res* 2009;95(3):183.
- [31] Lombardi Jr AV, Mallory TH, Vaughn BK, et al. Dislocation following primary posterior-stabilized total knee arthroplasty. *J Arthroplasty* 1993;8(6):633.
- [32] Lombardi Jr AV, Mallory TH, Waterman RA, Eberle RW. Intercondylar distal femoral fracture. An unreported complication of posterior-stabilized total knee arthroplasty. *J Arthroplasty* 1995;10(5):643.