



## Surgical technique

# What to Do When Revision Procedures Fail to Prevent Recurrent Hip Dislocation in THA? A Novel Simple Technique for Selected Patients

Hans Mau, MD, Mustafa Citak, MD, PhD, Thorsten Gehrke, MD, Hussein Abdelaziz, MD\*

Department of Orthopaedic Surgery, Helios ENDO-Klinik Hamburg, Hamburg, Germany

## ARTICLE INFO

## Article history:

Received 8 June 2020

Received in revised form

15 January 2021

Accepted 6 February 2021

Available online 7 March 2021

## Keywords:

Revision hip arthroplasty

Recurrent dislocation

Novel technique

## ABSTRACT

Failure to achieve postoperative stability is disappointing for both surgeons and patients after revision total hip arthroplasty. In particular, when available revision options have been exhausted. We describe our modification of previously reported surgical techniques without revising any component in a high-risk female patient with persistent hip dislocation despite multiple cup revisions using different implants. To stabilize the hip through the posterolateral approach, a synthetic polyethylene tube was used. This relatively simple, modified technique may be a solution in disappointing cases with failure to achieve hip stability in revision total hip arthroplasty.

© 2021 The Authors. Published by Elsevier Inc. on behalf of The American Association of Hip and Knee Surgeons. This is an open access article under the CC BY-NC-ND license (<http://creativecommons.org/licenses/by-nc-nd/4.0/>).

## Introduction

Hip instability represents a common complication after revision total hip arthroplasty. The risk of hip dislocation can be reduced by selecting appropriate prosthesis components, proper positioning, and meticulous surgical technique using soft tissue reconstruction [1]. Several risk factors have been identified as associated with dislocation after THA, including implant-related factors, surgical factors, and some patient comorbidities [2]. However, the risk and incidence of instability are higher after revision than primary THA [3,4]. Recurrent dislocations are surgically addressed, requiring revision of the acetabular component in many cases. To obtain higher stability, conversion to dual mobility cups or constrained implants may be needed [5]. Failure to achieve long-term postoperative stability is disappointing for surgeons and patients, particularly when available revision options have been exhausted. We describe our modification of previously reported surgical techniques without revising of any component in a high-risk patient with persistent, recurrent hip dislocation despite multiple cup revisions using different implants.

## Case report

## Patient and joint history

An informed consent was obtained from the patient. We report on a 76-year-old female patient with a body mass index of 24 kg/m<sup>2</sup>. Rheumatoid arthritis and restless leg syndrome were among her comorbidities. She was classified as an American Society of Anesthesiologists III patient. The operative history of the right hip started with a primary THA due to secondary osteoarthritis in 2015, followed by an ipsilateral primary total knee arthroplasty in 2017. Owing to a periprosthetic femoral fracture, open reduction and internal fixation was performed in 2017, which had to be revised in 2018 because of implant failure.

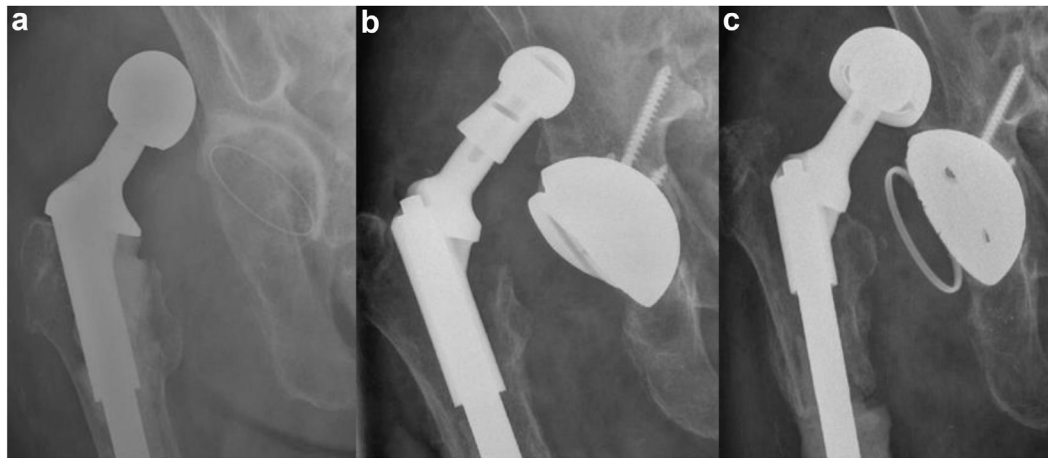
## At our hospital

## Revisions before infection

The first revision arthroplasty procedure at our hospital was performed in November 2018. The patient underwent a total femoral arthroplasty (TFA) because of nonunion of her femur fracture leading to an increased varus deformity of the right lower extremity. Two weeks later, the cemented polyethylene cup had been converted to a cemented dual mobility cup because of recurrent dislocation. The next revision procedure after 7 weeks included repositioning of the dual mobility cup and changing the head because of recurrent dislocation.

\* Corresponding author. Holstenstr. 2, 22767 Hamburg, Germany. Tel.: +49 40 3197 1105.

E-mail address: [habelaziz1984@gmail.com](mailto:habelaziz1984@gmail.com)



**Figure 1.** The recurrent posterior dislocation of the total femoral arthroplasty (TFA). (a) Polyethylene cup; (b) dual mobility cup; (c) tripolar constrained liner.

### *Infection and following revisions*

Four weeks later, the patient underwent one-stage exchange of the TFA using a combination of an acetabular revision shell and a cemented dual mobility cup due to a periprosthetic infection. This had been followed by a recurrent dislocation which was treated after 2 weeks with changing the femoral head to a longer one.

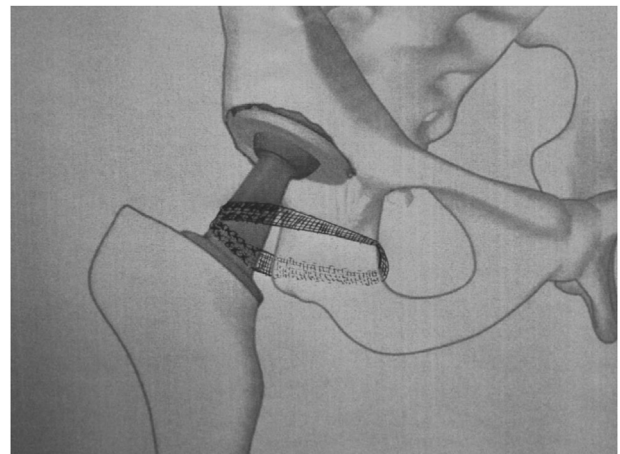
The right hip continued to dislocate, and a further cup conversion to a tripolar constrained liner had been performed 8 weeks later. Because of persistent instability with the constrained liner and failure of closed reduction, we decided to perform the described technique after 2 weeks to restrict the hip movement (Fig. 1). During the surgery, approximately 2 L of hematoma was evacuated. Subsequent dislocation did not occur after 12 months of follow-up, and the patient is independently able to walk on a wheeled walker.

### **Surgical technique**

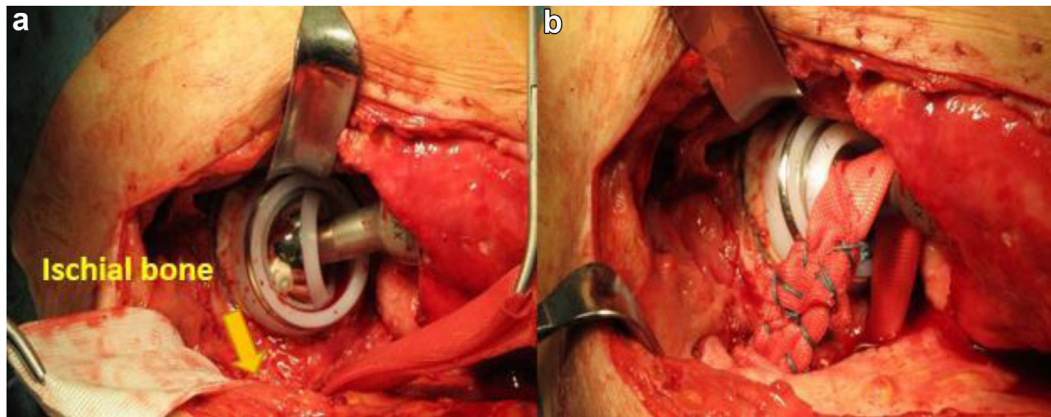
Surgery was performed through the posterolateral approach to the hip in the lateral decubitus position. Owing to unsuccessful open reduction attempts, the bipolar head of the constrained liner had first to be disassembled. There was no damage to the polyethylene liner. The bipolar head was then reassembled and reduced into the cup. The positioning of the prosthesis components, including the combined anteversion, was found to be appropriate. Therefore, the first author made the decision to stabilize the hip using a synthetic MUTARS attachment tube (implantcast, Buxtehude, Germany). This tube is used mainly in tumor surgery to reattach and reconstruct the soft tissue and was not being associated with an increased risk of infection [6]. It has a porous structure (polyethylene terephthalate), with a length of 300 mm, and is available in 35-mm and a 55-mm diameter. First, a tunnel was carefully created around the ischium using a DeBakey forceps via careful spreading movements. In the case of scarring from previous surgeries, the scar tissue had to be resected. Using a suture and the DeBakey forceps, the tube was passed through the tunnel and entwined around the neck of the TFA (Fig. 2). The tube was provisionally tensioned to the extent that the femoral head could not be pulled out of the cup. Multiple sutures with non-absorbable material were used to fix the tube with itself along the length of the neck (Fig. 3). The sciatic nerve was palpated during the surgery and partially dissected out in case of scarring to avoid its injury. We did not use any surrounding tissue remnant to augment the stabilization with the attachment tube. The final intraoperative examination revealed a hip flexion to 70° and internal rotation to 30°.

### **Discussion**

Recurrent dislocation after revision total hip arthroplasty for instability is a serious problem that may be followed by more complications leading to disability of the patients. A retrospective analysis yielded some revision-related predictors for this disappointing complication, such as small head size and an isolated exchange of the liner [7]. Our patient had a higher risk for recurrent dislocation due to the TFA, which is associated with extensive soft tissue dissection, including the hip stabilizers [8]. Besides, she has rheumatoid arthritis with contracted adductors of the hip and the tendency for internal rotation of both lower limbs. We revised the first acetabular component and converted it to a dual mobility cup based on our good experience with such cups to achieve postoperative stability. This was in turn used for the reimplantation during the one-stage exchange for periprosthetic infection. During the next revision for instability, the components' positioning was optimal, and only the head was exchanged. The last revision of the acetabular component in our case was the conversion into a constrained liner, which did not resolve the problem. Constrained liners are one of the treatment methods for instability; however, higher mechanical failure rates and re-revisions have been reported, especially after further revision to another constrained implant [9]. Therefore, after checking the cup



**Figure 2.** Diagrammatic illustration of our technique.



**Figure 3.** (a) The tube was passed through a previously created tunnel around the ischium. (b) Under tensioning of the tube, multiple sutures with non-absorbable material were used to fix the tube with itself around the neck.

position, stem anteversion, and tension and offset during the last revision, we decided to perform the current technique rather than revise the prosthetic components. Some authors have previously described different techniques using synthetic ligaments or allograft to restrict the movement that could lead to recurrent dislocation, thus stabilizing the hip [10–12]. Fujishiro et al. [12] described an anterior reinforcement of the iliofemoral ligament using an artificial Leeds-Keio ligament (developed by the University of Leeds, UK and Keio University, Japan) after a recurrent anterior dislocation. Lavigne et al. [10] reported on 60% overcome rate of a recurrent posterior dislocation at 3 years follow-up using Achilles tendon allograft as a posterior restraint. The allograft was fixed to the lower ilium with 2 screws and the proximal femur with a cable [11]. Barbosa et al. [11] used the patellar Soffix ligament prosthesis (Surgicraft Ltd., Worcester, UK) in 4 patients with recurrent posterior dislocation. The ligament was looped around the prosthesis neck and attached to the superior pubic ramus with a screw through the anterior approach. No recurrence of the dislocation occurred after 2 years [11]. We performed our technique through the same previous approach and benefiting from the good exposure of the posterior approach. Furthermore, there is no need for any screw fixation. In the current case, we could overcome the persistent, frustrating hip instability with immobility for months, and the patient regained her hip stability for over 1 year postoperatively. Despite a relatively limited range of motion of her hip, the patient was satisfied with the surgery result and had only mild tolerable pain. Nevertheless, this modified, relatively simple technique should be validated on many patients with longer follow-up. Meanwhile, a total of 7 patients had undergone the described procedure. The mean age of them is 81 years (range, 77 to 87). Four of them did not encounter further hip dislocations at a mean follow-up of 5 months. All of them have dual mobility cups. The fifth patient had to be revised because of hip instability at 2 months postoperatively. In that case, the cup had been revised to a dual mobility cup, and the current technique was repeated. We concluded that our technique could result in a better outcome with concurrent dual mobility cups, which might be correlated to the increased jumping distance of the bipolar head out of the cup. We aim to follow up our small series and to include more patients to assess the effectiveness of the ENDO-technique in this specific group of patients.

### Conflict of interests

Outside the article, one or more of the authors of this article have disclosed following disclosures: M. Citak is a paid consultant for Waldemar Link, Hamburg. T. Gehrke is a paid consultant for Waldemar Link, Hamburg, Zimmer, Warsaw, and Ceramtec. All the other authors declare that they have no conflict of interest regarding this article.

For full disclosure statements refer to <https://doi.org/10.1016/j.artd.2021.02.006>.

### References

- [1] Faldini C, Stefanini N, Fenga D, et al. How to prevent dislocation after revision total hip arthroplasty: a systematic review of the risk factors and a focus on treatment options. *J Orthop Traumatol* 2018;19(1):17.
- [2] Seagrave KG, Troelsen A, Malchau H, Husted H, Gromov K. Acetabular cup position and risk of dislocation in primary total hip arthroplasty. *Acta Orthop* 2017;88(1):10.
- [3] Kosashvili Y, Backstein D, Safir O, Lakstein D, Gross AE. Dislocation and infection after revision total hip arthroplasty: comparison between the first and multiply revised total hip arthroplasty. *J Arthroplasty* 2011;26(8):1170.
- [4] Jo S, Jimenez Almonte JH, Sierra RJ. The cumulative risk of re-dislocation after revision THA performed for instability increases close to 35% at 15years. *J Arthroplasty* 2015;30(7):1177.
- [5] Charissoux JL, Asloum Y, Marcheix PS. Surgical management of recurrent dislocation after total hip arthroplasty. *Orthop Traumatol Surg Res* 2014;100(1 Suppl):S25.
- [6] Gosheger G, Hillmann A, Lindner N, et al. Soft tissue reconstruction of megaprotheses using a trevira tube. *Clin Orthop Relat Res* 2001;264.
- [7] Carter AH, Sheehan EC, Mortazavi SM, Purtill JJ, Sharkey PF, Parvizi J. Revision for recurrent instability: what are the predictors of failure? *J Arthroplasty* 2011;26(6 Suppl):46.
- [8] DeRogatis MJ, Issack PS. Total femoral replacement as a salvage operation for the treatment of massive femoral bone loss during revision total hip arthroplasty. *JBJs Rev* 2018;6(5):e9.
- [9] Hernandez NM, Sierra RJ, Trousdale RT. Constrained liner revision is less effective with each subsequent constrained liner revision at preventing instability. *J Arthroplasty* 2019;34(7S):S282.
- [10] Lavigne MJ, Sanchez AA, Coutts RD. Recurrent dislocation after total hip arthroplasty: treatment with an Achilles tendon allograft. *J Arthroplasty* 2001;16(8 Suppl 1):13.
- [11] Barbosa JK, Khan AM, Andrew JG. Treatment of recurrent dislocation of total hip arthroplasty using a ligament prosthesis. *J Arthroplasty* 2004;19(3):318.
- [12] Fujishiro T, Nishikawa T, Takikawa S, Saegusa Y, Yoshiya S, Kurosaka M. Reconstruction of the iliofemoral ligament with an artificial ligament for recurrent anterior dislocation of total hip arthroplasty. *Arthroplasty* 2003;18(4):524.