

## Case report

# Bone Cement Hypersensitivity in Patients With a Painful Total Knee Arthroplasty: A Case Series of Revision Using Custom Cementless Implants

Sheila Pahlavan, BS <sup>a, b</sup>, Vishal Hegde, MD <sup>a, c</sup>, Daniel N. Bracey, MD, PhD <sup>a, d</sup>, Jason M. Jennings, MD, DPT <sup>a, e, \*</sup>, Douglas A. Dennis, MD <sup>a, e, f, g</sup>

<sup>a</sup> Colorado Joint Replacement, Denver, CO, USA

<sup>b</sup> University of Colorado School of Medicine, Aurora, CO, USA

<sup>c</sup> Department of Orthopaedic Surgery, The Johns Hopkins University, Baltimore, MD, USA

<sup>d</sup> Department of Orthopaedic Surgery, University of North Carolina, Chapel Hill, NC, USA

<sup>e</sup> Department of Mechanical and Materials Engineering, University of Denver, Denver, CO, USA

<sup>f</sup> Department of Orthopaedics, University of Colorado School of Medicine, Denver, CO, USA

<sup>g</sup> Department of Biomedical Engineering, University of Tennessee, Knoxville, TN, USA

## ARTICLE INFO

## Article history:

Received 1 April 2021

Received in revised form

3 June 2021

Accepted 5 June 2021

Available online 9 August 2021

## Keywords:

Cement allergy

TKA allergy

TKA hypersensitivity

## ABSTRACT

Little is known about patients with bone cement hypersensitivity after total knee arthroplasty (TKA). We present 7 patients implanted with 8 TKAs with clinical failure and a cement hypersensitivity diagnosis. All demonstrated hypersensitivity to bone cement via skin patch and/or lymphocyte transformation testing. All 7 patients also showed hypersensitivity to metal, most commonly nickel. Patients underwent custom cementless TKA revision. Prerevision and postrevision outcome measures, radiographs, intraoperative findings, and postrevision complications are reported. Functional scores improved after revision except Veterans RAND-12 mental component scores, which declined. Four patients continue to exhibit symptoms postoperatively, while one patient has had 3 additional surgical procedures. Patients presenting with bone cement hypersensitivity after TKA are particularly challenging. Evidence-based guidelines are lacking, and revision surgery may not relieve the presenting symptoms.

© 2021 The Authors. Published by Elsevier Inc. on behalf of The American Association of Hip and Knee Surgeons. This is an open access article under the CC BY-NC-ND license (<http://creativecommons.org/licenses/by-nc-nd/4.0/>).

## Introduction

The clinical significance of hypersensitivity reactions to orthopedic implant materials continues to be a controversial topic. When present, these reactions are thought to result in an array of symptoms, including generalized or localized dermatitis, aseptic inflammation, persistent pain and swelling, and on rare occasions, aseptic loosening of the implant [1]. The management of a patient who presents with a painful total knee arthroplasty (TKA) and positive hypersensitivity testing is a challenge, as robust clinical validation of the significance of existing cutaneous and in vitro tests is lacking [2]. Yet most published reports, which focus specifically on an allergic reaction to metal components, do indicate improved outcomes in patients undergoing revision [3–5]. In addition,

although not advocating widespread testing, published algorithms continue to recommend taking positive test results into consideration when planning revision TKA [2,6].

Severe hypersensitivity reactions to acrylic bone cement and its polymerization additives (benzoyl peroxide and N, N-dimethyl-p-toluidine) are now being posited as a cause for concern in TKA, similar to metal hypersensitivity [7–11]. Many centers now include the components of bone cement along with metal alloys in allergy testing panels [12,13]. In spite of this growing interest, there is currently a paucity of data reporting on patients undergoing revision for a poorly functioning TKA in the context of a bone cement allergy.

We report a case series of 7 patients with 8 painful TKAs who underwent revision using custom cementless components after being diagnosed with an allergy to a component of bone cement.

## Case series

This case series analysis was approved by our institutional review board before initiation of this study. Our institution's

\* Corresponding author. 2535 S Downing St. Suite 100, Denver, CO 80210, USA. Tel.: 720-524-1367.

E-mail address: [roseannjohnson@centura.org](mailto:roseannjohnson@centura.org)

<https://doi.org/10.1016/j.artd.2021.06.001>

2352-3441/© 2021 The Authors. Published by Elsevier Inc. on behalf of The American Association of Hip and Knee Surgeons. This is an open access article under the CC BY-NC-ND license (<http://creativecommons.org/licenses/by-nc-nd/4.0/>).

prospective, longitudinally maintained total joint arthroplasty database was used to identify all patients who had a documented preoperative cement allergy and underwent revision TKA with a custom cementless implant. The cementless implants were custom made for the patient by the vendor (Biomet or Depuy) but did not require institutional review board or Food and Drug Administration clearance (Table 1). Patients were excluded if they did not have a minimum of 1-year follow-up postoperatively. Informed consent was obtained before their participation in the database. Patient details were recorded, including demographic data, index TKA components, preoperative workup, and allergy testing method and results. Intraoperative findings at revision surgery were noted based on operative report documentation. Prerevision and post-revision radiographs and outcome measures including range of motion, Knee Society Scores (KSS), and Veterans RAND (VR)-12 mental (MCS) and physical component scores (PCS) were reviewed. Postrevision complications and subsequent revision surgeries were also reported.

Between 2011 and 2019, 7 patients (3 female and 4 male) presented to our institution with 8 TKAs that underwent revision by 3

different surgeons due to a reported cement allergy (Fig. 1). Details are summarized in Table 1. No patient had a history of arthroscopy before their primary TKA. The revisions were performed using conventional techniques, and all 3 surgeons are full-time joint replacement specialists. Patients underwent revision at an average of 66.3 months after their index TKA. Three out of 8 TKAs had a previous revision of their index TKA at an average of 50 months before their cementless revision. Five of 8 TKAs did not have a period of time after their index TKA when they were functioning well. The most common complaints before revision were pain (8/8) and chronic effusions (5/8). Physical examination findings included both arthrofibrosis and instability. No patients had any cutaneous findings.

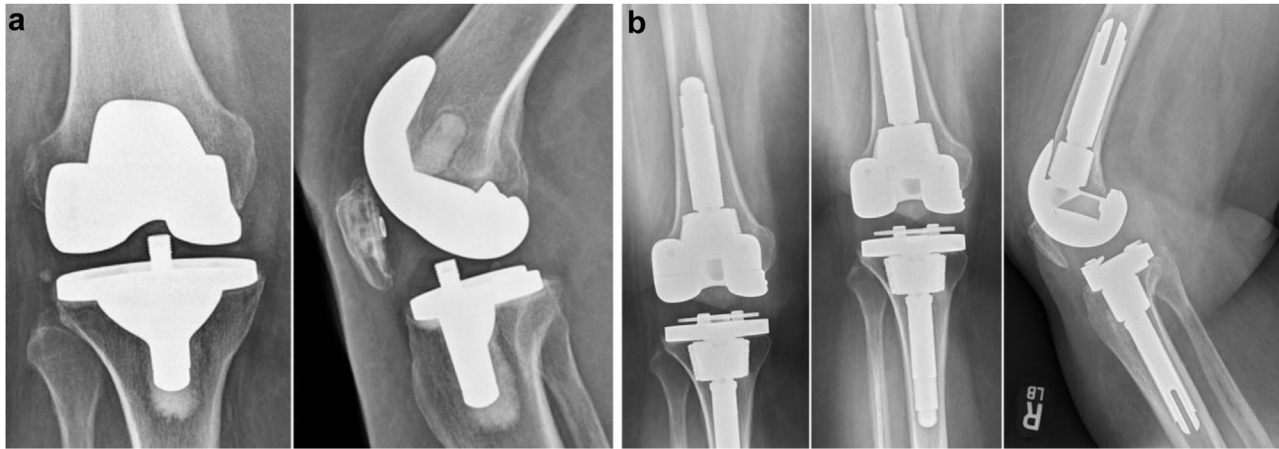
Before revision surgery, patients underwent extensive blood, synovial fluid, radiographic, and allergy testing to rule out other causes of implant failure. All 7 patients had already undergone testing for a hypersensitivity reaction before presenting to our institution. No surgeon at our institution routinely screens for these allergies. Details are summarized in Table 2. The most common method of hypersensitivity testing used was patch testing (7 out of

**Table 1**  
Preoperative and intraoperative patient data.

Patient	Age	Sex	BMI	Date of primary surgery	Side	Primary implants	Prior revisions	Symptoms	Preoperative labs/ aspiration	Date of cementless revision surgery	Intraoperative findings	Revision implants
1	72	Male	26.7	6/2006	Right	Stryker Triathlon	8/2006: Revision to Depuy PFC Sigma PS 3/2009: Liner exchange	Pain, chronic effusions, instability	ESR: 1 CRP: 2.9 Cell count: 420 PMN: 24%	7/2014	None	Biomet Vanguard custom titanium alloy, hydroxyapatite coated, plasma sprayed
2	69	Female	39.5	12/2017	Right	Aesculap Vega PS	None	Pain, chronic effusions, arthrofibrosis	ESR: 13 CRP: 8.39 <sup>a</sup> Cell count: 422 PMN: 57%	5/2019	Femoral component loosening	Biomet Vanguard custom titanium alloy, porous coated, ion bombarded
3	71	Male	32	4/2009	Left	Biomet Vanguard PS	5/2010: Liner exchange	Pain, chronic effusions, arthrofibrosis	ESR: 5 CRP: 2.9 Cell count: 33 PMN: 20%	7/2011	None	Depuy PFC Sigma TC3 custom porous coated
4	59	Female	26.3	11/2009	Left	Stryker Triathlon PS	None	Pain, chronic effusions	ESR: 4 CRP: 2.9 Cell count: 1031 PMN: 65%	4/2012	Instability	Biomet Vanguard custom titanium alloy, porous coated, plasma sprayed
5	68	Male	26.2	10/2001	Right	Depuy PFC Sigma PS	2/2012: Liner exchange 11/2013: Revision to Depuy PFC Sigma	Pain, chronic effusions, instability	ESR: 4 CRP: 2.9 Cell count: 436 PMN: 47%	11/2019	Femoral component loosening	Biomet Vanguard custom titanium alloy, porous coated, ion bombarded
6	71	Female	32	7/2012	Left	Smith & Nephew Legion CR (Oxinium)	None	Pain, instability	ESR: 5 CRP: 2.9 Cell count: 240 PMN: 8%	2/2015	None	Biomet Vanguard custom titanium alloy, hydroxyapatite coated, ion bombarded
7A	65	Male	24	6/2014	Right	Depuy Attune PS	None	Pain, arthrofibrosis	ESR: 2 CRP: 2.9 Cell count: 477 PMN: 19%	9/2018	None	Biomet Vanguard custom titanium alloy, porous coated, ion bombarded
7B	65	Male	24	9/2014	Left	Depuy Attune PS	None	Pain, arthrofibrosis	ESR: 2 CRP: 2.9 Cell count: 268 PMN: 13%	10/2019	Patellar component loosening, instability	Biomet Vanguard custom titanium alloy, porous coated, ion bombarded

BMI, body mass index; CRP, C-reactive protein; PMN, polymorphonuclear; ESR, erythrocyte sedimentation rate; ROM, range of motion.

<sup>a</sup> Elevated value.



**Figure 1.** (a) Preoperative radiographs of patient 2. (b) Postoperative radiographs of patient 2 after undergoing custom cementless revision TKA.

8) and lymphocyte transformation testing (LTT) (Orthopedic Analysis, Chicago, IL) (5 out of 8). All 7 patients also tested positive for a metal allergen, most commonly nickel. Four out of 7 patients (patients 1, 3, 5, and 7) underwent more than one type of allergy testing. All 4 patients had differing results from each method of hypersensitivity testing as seen in [Table 2](#).

At the time of revision, it was determined that 3 of the 8 TKAs had loose components, and 2 had significant instability. Four of the 8 did not have any other documented mode of failure aside from cement hypersensitivity. All patients were revised to custom cementless implants. Intramedullary guides were used to cut the distal femur and tibia. Metaphyseal fixation with either cones or sleeves were used in both the femur and tibia in all cases. Femoral and tibial augmentation was used when indicated based on bone loss. No bone grafting or bone slurry was used.

Average length of follow-up after revision was 44.2 months. Details are summarized in [Table 3](#). Average range of motion improved from 103.1 degrees preoperatively to 118.9 degrees postoperatively. The KSS improved above the minimal clinically important difference (MCID) of 6 in 6 knees, with the average KSS improving from 51.3 preoperatively to 71.9 postoperatively [14]. There was also an improvement in VR-12 PCS above the MCID of 5 in 5 knees, with the average VR-12 PCS improving from 27.2 preoperatively to 33.6 postoperatively [15]. The VR-12 MCS improved

above the MCID of 5 in 2 knees, with the average declining from 52.3 preoperatively to 50.0 postoperatively. One patient required 3 subsequent revisions, one for tibial component loosening requiring tibial component revision 1 year after index cementless revision, a second for recurrent hemarthroses requiring a complete synovectomy and liner exchange 2 and a half years after index cementless revision, and the third for lateral patellar facet pain requiring a lateral facetectomy 6 years after index cementless revision ([Table 4](#)). Four patients continue to have postoperative symptoms: Two continue to experience chronic effusions, another suffers from end-of-stem pain from the tibial component, and the fourth continues to have significant chronic knee pain. Of the 4 patients with an isolated cement allergy, 2 have had a resolution of symptoms while 2 continue to experience symptoms: Patient 3 continues to have chronic effusions, while patient 7 has pain at the end of his tibial stem.

## Discussion

This case series reports on 7 patients who presented to our institution with 8 painful TKAs and documented cement allergy. All patients underwent revision TKA with custom cementless revision implants. Chronic effusions, arthrofibrosis, pain, and instability were among the presenting symptoms and physical examination findings. Preoperative and intraoperative investigation revealed that 4 of the 8 knees did not have any other modes of “failure.” Prerevision and postrevision functional outcome measures showed trends of improvement, except for VR-12 MCS. Four patients continue to experience symptoms, including chronic effusions, end-of-tibial stem pain, and chronic knee pain, and one patient has had 3 additional revision surgeries.

While there is extensive literature on allergic reactions to metal components in TKA, less attention has been paid to elements of bone cement [2,4–6,16,17]. There is a lack of clinical evidence to support a causal relationship between hypersensitivity to acrylics such as polymethyl methacrylate, polymerization additives (N, N-dimethyl-p-toluidine), initiators (benzoyl peroxide), stabilizers (hydroquinone), and radiocontrast media (zirconium dioxide and barium sulfate) and knee replacement failure [10]. Patients can have previous exposure to acrylics in dental procedures, paint, hearing aids, cosmetics, inks, surgical tape, and rubber stamp making among various other materials [18]. A patient history can be vital in discovering any exposure resulting in an allergic reaction to these materials in the past. Similar to prior reports, chronic effusions were the main presenting symptom in 5 out of 8 TKAs, and

**Table 2**  
Hypersensitivity testing results.

Patient	Patch testing	LTT
1	Nickel	Bone cement particles, nickel, titanium
2	NT	Bone cement monomer, nickel, cobalt
3	Benzoyl peroxide	Nickel
4	Bone cement monomer part A and bone cement powder part B, nickel	NT
5	Negative	#1: Bone cement monomer #2: Bone cement particles, aluminum, nickel, titanium
6	Cobalt, nickel, bone cement, bone cement monomer A, benzoyl peroxide	NT
7A	Bone cement monomer part A and bone cement powder part B	Cobalt, vanadium, zirconium
7B	Bone cement monomer part A and bone cement powder part B	Cobalt, vanadium, zirconium

NT, not tested.

**Table 3**  
Functional scores.

Patient	Postoperative follow-up (mo)	Preoperative functional scores							Postoperative functional scores						
		ROM extension	ROM flexion	ROM score	Total function	Total KSS	VR-12 MCS	VR-12 PCS	ROM extension	ROM flexion	ROM score	Total function	Total KSS	VR-12 MCS	VR-12 PCS
1	60	0	127	25	60	60	40	22	3	125	24	55	59	42	28
2	12	0	66	13	75	58	52	37	0	114	23	70	98	61	48
3	96	0	120	24	50	49	63	21	0	115	23	50	58	59	35
4	90	0	110	22	60	39	20	33	0	115	23	45	39	18	24
5	12	0	124	25	50	40	74	19	0	120	24	45	59	65	21
6	48	0	123	25	30	65	52	27	0	130	25	70	95	21	26
7A	24	5	85	16	90	49	52	34	0	115	23	100	88	67	43
7B	12	0	75	15	80	50	65	24	0	120	24	100	79	67	43

ROM, range of motion.

component loosening was observed in 3 of 8 TKAs in this series [7,8]. Unlike previous reports, cutaneous manifestations and pseudotumors were not observed [7,10,11].

The allergic reaction to bone cement or its components is considered a type-IV hypersensitivity reaction that develops in a genetically predisposed patient [19]. A component of bone cement combines with a large carrier to create a neoantigen. This neoantigen then stimulates an immune response that can have both local and systemic effects. Allergic reactions to orthopedic implants can introduce an array of symptoms including generalized or localized dermatitis, persistent pain and swelling, wound-healing issues, aseptic inflammation, and in rare occasions, aseptic loosening of the implant [17]. Histological analysis can demonstrate increased CD3 expression and lymphocytes mediated perivascular infiltration [8]. In addition, some literature suggests that sensitization to one allergen can facilitate sensitization to an unrelated chemical [20]. This has most commonly been observed with the association of nickel and cobalt, although there is some debate as to whether this is simply the result of multiple sensitizations through exposure [21,22]. Although no specific link has been established in the literature, this may explain the concomitant metal allergies found during hypersensitivity testing in these patients.

To help aid in the diagnosis of a bone cement allergy, 2 different modes of testing were used: LTT (which measures lymphocyte reactivity upon exposure to bone cement components), and skin patch hypersensitivity testing (which identifies dermatitis when contact allergens are exposed to the skin). All patients displayed reactions to bone cement components either through LTT or patch testing. It is interesting to note that none of the 4 patients who underwent both patch testing and LTT had consistent hypersensitivity reactions between the 2 tests. This may be partially explained by the difficulty in evaluating benzoyl peroxide allergy using patch testing. More highly concentrated benzoyl peroxide solutions (eg, 1%) can cause an irritative skin reaction, leading to a false-positive

**Table 4**  
Postoperative patient data.

Patient	Subsequent revisions	Current symptoms
1	-	None
2	-	None
3	-	Chronic effusions
4	2/2013: Tibia revision for aseptic loosening 12/2014: Synovectomy for recurrent hemarthrosis 6/2018: Lateral facetectomy for lateral patellar facet pain	Chronic pain
5	-	Chronic effusions
6	-	None
7A	-	End of tibial stem pain
7B	-	None

result [23]. In addition, prior contact with benzoyl peroxide in the context of its use as a topical acne medication is also a predisposition for an irritant skin reaction on patch testing [24].

It is also important to note that the validity of both hypersensitivity testing methods has been questioned. Patch testing has been criticized for overdiagnosing hypersensitivity reactions, as the dermal hypersensitivity effector cells, Langerhans cells, are different from the periprosthetic hypersensitivity effector cells, namely dendritic cells and macrophages [17,25]. The Langerhan's cells which react on the skin are not present inside the joint itself, making the clinical significance of their reactivity unclear. In the context of metal allergy, it has been demonstrated that there is a lack of correlation between LTT reactivity and an immune reaction as demonstrated by intraoperative histopathology [16]. Thus, it is important to emphasize that a connection between positive results from either of these 2 testing modalities and bone cement allergy as a true cause of TKA failure is yet to be definitively established.

Although 4 of the 8 revised TKAs showed no other mode of failure, 3 patients did have concomitant loosening of one of their TKA components. This raises the question as to whether component loosening is due to the hypersensitivity reaction to bone cement, or vice versa. A previous case series by Haddad et al. described 7 patients who demonstrated rapid aseptic loosening of their cemented total hip arthroplasties and were found to have a hypersensitivity reaction to bone cement [26]. It is theorized that the allergy to bone cement may cause a significant inflammatory reaction which may then accelerate the process of aseptic loosening. Conversely, it may be that the very act of cementation of an implant can predispose a patient to a positive bone cement allergy test. One study of 42 patients who received a cemented hip prosthesis found a 25% positive patch test result for methyl methacrylate at 6 months postoperatively. This is in contrast to a study that found the overall prevalence of positive acrylate/methacrylate patch testing to be 1.4% and 1.0% in Sweden and Singapore, respectively [27].

Although patients in this series generally showed a trend toward improvement, half of the knees in this series continued to have symptoms postoperatively. While there may be a role for the implantation of custom cementless implants in these patients, the high rate of continued complaints makes it difficult to attribute their preoperative symptoms solely to a diagnosis of cement hypersensitivity. Surgeons involved in the design of custom cementless revision implants for patients with a bone cement hypersensitivity should be aware of concomitant metal hypersensitivities, as all patients in this series also tested positive for a metal allergen. In spite of these findings, patients presenting with a bone cement allergy and a painful TKA present a considerable diagnostic dilemma. These patients should be extensively counseled about the controversial nature of a bone cement hypersensitivity diagnosis and the fact that this challenging reconstruction may not provide a favorable result in all cases.

## Summary

Patients who present with hypersensitivity reactions to components of bone cement and a painful TKA present a considerable challenge. It remains unclear whether these hypersensitivity reactions are the sole cause of failure, are a coincidental finding that is associated with a more traditional mechanical mode of TKA failure, or perhaps both. When evaluating a patient with a painful TKA, a bone cement hypersensitivity should be treated as a diagnosis of exclusion, with traditional modes of failure (infection, loosening, instability, malrotation) first investigated and appropriately addressed at the time of revision surgery. If the diagnosis remains unclear, hypersensitivity testing with LTT is recommended, due to the difficulty in evaluating benzoyl peroxide allergy using patch testing. Revision implant selection should be carefully considered, as all the patients in this series also presented with a variety of metal allergies on testing. Cementless revision implants in this series provided a good result at the latest follow-up. Additional investigation into both the diagnosis and pathophysiology of bone cement hypersensitivity is necessary to further elucidate its role in TKA failure.

## Conflicts of interest

The authors declare that they have no known competing financial interests or personal relationships that could have appeared to influence the work reported in this article.

## Informed patient consent

The author(s) confirm that informed consent has been obtained from the involved patient(s) or if appropriate from the parent, guardian, power of attorney of the involved patient(s); and, they have given approval for this information to be published in this case report (series).

## References

- [1] Schuh A, Thomas P, Reinhold R, Holzwarth U, Zeiler G, Mahler V. Allergic reaction to components of bone cement after total knee arthroplasty. *Zentralbl Chir* 2006;131(5):429.
- [2] Lachiewicz PF, Watters TS, Jacobs JJ. Metal hypersensitivity and total knee arthroplasty. *J Am Acad Orthop Surg* 2016;24(2):106.
- [3] Thomas P. Allergic reactions to implant materials. *Orthopde* 2003;32(1):60.
- [4] Law JJ, Morris MJ, Hurst JM, Berend KR, Lombardi AV, Crawford DA. Early outcomes of an alternative bearing surface in primary total knee arthroplasty in patients with self-reported metal allergy. *Arthroplast Today* 2020;6(4):639.
- [5] Zondervan RL, Vaux JJ, Blackmer MJ, Brazier BG, Taunt CJ. Improved outcomes in patients with positive metal sensitivity following revision total knee arthroplasty. *J Orthop Surg Res* 2019;14(1):1.
- [6] Faschingbauer M, Renner L, Boettner F. Allergy in total knee replacement. Does it exist?: review article. *HSS J* 2017;13(1):12.
- [7] Bircher A, Friederich NF, Seelig W, Scherer K. Allergic complications from orthopaedic joint implants: the role of delayed hypersensitivity to benzoyl peroxide in bone cement. *Contact Dermatitis* 2012;66(1):20.
- [8] Fröschen FS, Gravius N, Lau JF, et al. A case series of cementless revision total knee arthroplasty in patients with benzoyl peroxide allergy. *Int Orthop* 2019;43(10):2323.
- [9] Edwards SA, Gardiner J. Hypersensitivity to benzoyl peroxide in a cemented total knee arthroplasty: Cement allergy. *J Arthroplasty* 2007;22(8):1226.
- [10] Treudler R, Simon JC. Benzoyl peroxide: is it a relevant bone cement allergen in patients with orthopaedic implants? *Contact Dermatitis* 2007;57.
- [11] Kenan S, Kahn L, Haramati N, Kenan S. A rare case of pseudotumor formation associated with methyl methacrylate hypersensitivity in a patient following cemented total knee arthroplasty. *Skeletal Radiol* 2016;45:1115.
- [12] Orthopedic analysis: metal hypersensitivity testing "LTT" [Internet]. <https://www.orthopedicanalysis.com/order-testing-panel/>; 2020. [Accessed 12 October 2020].
- [13] National Jewish Health. Joint replacement problems [Internet]. <https://www.nationaljewish.org/for-professionals/referrals-and-consults/joint-replacement-problems/>; 2020. [Accessed 12 October 2020].
- [14] Maredupaka S, Meshram P, Chatte M, Kim WH, Kim TK. Minimal clinically important difference of commonly used patient-reported outcome measures in total knee arthroplasty: review of terminologies, methods and proposed values. *Knee Surg Relat Res* 2020;32(1):1.
- [15] Kazis LE, Miller DR, Skinner KM, et al. Patient-reported measures of health: the Veterans health study. *J Ambul Care Manage* 2004;27(1):70.
- [16] Yang S, Dipane M, Lu CH, Schmalzried TP, McPherson EJ. Lymphocyte transformation testing (LTT) in cases of pain following total knee arthroplasty: little relationship to histopathologic findings and revision outcomes. *J Bone Joint Surg Am* 2019;101(3):257.
- [17] Hallab N, Merritt K, Jacobs JJ. Metal sensitivity in patients with orthopaedic implants. *J Bone Joint Surg Am* 2001.
- [18] Kaplan K, Valle CJ Della, Haines K, Zuckerman JD. Preoperative identification of a bone-cement allergy in a patient undergoing total knee arthroplasty. *J Arthroplasty* 2002;17(6):788.
- [19] Guid J. Practical contact dermatitis: a handbook for the practitioner. *Arch Dermatol* 1995.
- [20] Torres F, Das Graças M, Melo M, Tosti A. Management of contact dermatitis due to nickel allergy: an update. *Clin Cosmet Investig Dermatol* 2009;2:39.
- [21] Lammintausta K, Kalimo K. Do positive nickel reactions increase nonspecific patch test reactivity? *Contact Dermatitis* 1987;16:160.
- [22] Lammintausta K, Pitkänen O-P, Kalimo K, Jansen CT. Interrelationship of nickel and cobalt contact sensitization. *Contact Dermatitis* 1985;13(3):148.
- [23] Uter W, Rämisch C, Aberer W, et al. The European baseline series in 10 European Countries, 2005/2006 - results of the European surveillance system on contact allergies (ESSCA). *Contact Dermatitis* 2009.
- [24] Geier J, Lessmann H, Becker D, Thomas P. Allergologische Diagnostik bei Verdacht auf Implantatunverträglichkeit: Hinweise für die PraxisAllergy diagnostics in suspected implant intolerance: practical approach. *Der Hautarzt* 2008.
- [25] Cousen PJ, Gawkrödger DJ. Metal allergy and second-generation metal-on-metal arthroplasties. *Contact Dermatitis* 2012;66(2):55.
- [26] Haddad FS, Cobb AG, Bentley G, Levell NJ, Dowd PM. Hypersensitivity in aseptic loosening of total hip replacements. The role of constituents of bone cement. *J Bone Joint Surg Br* 1996.
- [27] Goon ATJ, Bruze M, Zimerson E, Goh CL, Soo-Quee Koh D, Isaksson M. Screening for acrylate/methacrylate allergy in the baseline series: our experience in Sweden and Singapore. *Contact Dermatitis* 2008.