

Surgical technique

Utilizing a Prefabricated Antibiotic-Impregnated Articular Spacer Combined With an Intramedullary Device for Significant Femoral Bone Loss in Periprosthetic Hip Infection

Justin Stafford, DO^{*}, Mitchell Hunter, DO, Hyrum Judd, DO, Arturo Corces, MD

Larkin Community Hospital, Department of Orthopaedic Surgery, South Miami, FL, USA

ARTICLE INFO

Article history:

Received 3 November 2021

Received in revised form

8 March 2022

Accepted 10 March 2022

Available online 18 May 2022

Keywords:

THA

Revision

Infection

PJI

ABSTRACT

Periprosthetic joint infection can be a devastating complication following total hip arthroplasty, which often requires a lengthy treatment course that is fraught with complications. There are various types of antibiotic-impregnated spacers that can be used to treat periprosthetic hip infections, with articulating spacers being utilized frequently with the goal of preserving patient range of motion and functionality. Many of these articulating spacers have pre-set sizes and stem options, which accommodate the majority of patients. However, when significant femoral bone loss is evident at the time of revision surgery, many articulating spacer options are not sufficient to provide stability, and custom modifications of available spacer constructs may be needed to fill the bony void. The goal of this article is to report a surgical technique that can be used in the salvage of failed antibiotic-impregnated spacers where severe femoral bone loss is present.

© 2022 Published by Elsevier Inc. on behalf of The American Association of Hip and Knee Surgeons. This is an open access article under the CC BY-NC-ND license (<http://creativecommons.org/licenses/by-nc-nd/4.0/>).

Introduction

Periprosthetic joint infection (PJI) following total hip arthroplasty poses a difficult dilemma for reconstructive joint surgeons. Despite reported success rates of over 90% for 2-stage reimplantation, multiple revision surgeries are often necessary to eradicate infection and achieve a successful outcome [1,2]. During these revision procedures, surgeons frequently encounter distorted soft tissues with extensive fibrosis, osteolysis secondary to necrosis and infection, and poor vascular supply to the hip region.

In cases of severe osteolysis or abductor deficiency, static spacers have traditionally been used to avoid short-term complications such as dislocation and/or instability [3,4–6]. However, when these factors are not present, articulating spacers are favored to better preserve patient range of motion, decrease hospital length of stay, minimize bone loss, and facilitate spacer removal during reimplantation [3,7]. Surgeons may utilize various types of articulating spacers such as self-constructed spacers of polymethylmethacrylate and antibiotics over a “femoral backbone” [8,9], molded hip systems

like the prosthesis with antibiotic-loaded acrylic cement [10], or prefabricated commercial spacers. Although prefabricated spacers are costlier, they can decrease total surgical time and provide a high local concentration of antibiotics secondary to their significant effective surface area [11].

Articulating spacer placement can be extremely challenging in cases of femoral fracture or extensive bony osteomyelitis or necrosis [12]. Complication rates of 19.5%–50% with spacer dislocation, fracture, and femoral fracture about the spacer [13,14] have been reported. Recent studies have shown 5-year infection-free survival rates of only 64% in patients who require multiple hip spacer exchanges [15]. Here we present a surgical technique utilizing a prefabricated articulating antibiotic-impregnated spacer femoral head in combination with an intramedullary device encapsulated by antibiotic cement for construction of a proximal femoral spacer when significant bone loss is present.

Surgical technique

Patient background

This is the case of a 71-year-old female with a complex course of chronic right hip PJI. The patient's course has had numerous

^{*} Corresponding author. Larkin Community Hospital, Department of Orthopaedic Surgery, South Miami, FL, USA. Tel.: +1 305 284 7500.

E-mail address: Justin.stafford111@gmail.com

complications due to trauma (a dissociation of the cement spacer and fracture) and continued PJI despite intravenous-directed antibiotic therapy, spacer exchange, and irrigation and debridement. The patient was seen in clinic 2 weeks after completion of antibiotic therapy and aspiration of the right hip demonstrating continued chronic infection with aspiration growth of *Pseudomonas aeruginosa* but with erythrocyte sedimentation rate 25 mm/h and C-reactive protein 2.54 mg/L. Radiographic evidence also showed extensive femoral sequestrum and an incomplete femoral shaft fracture (Fig. 1). The patient was sent to the hospital with recommendation of revision surgery. Due to the chronicity of the infection and development of sequestrum, radical resection of the proximal half of the patient's femur was necessary to obtain healthy bleeding bone. This created the challenge of creating a spacer for the patient that would be suitable at this stage with the extensive bone loss.

Approach

The patient was placed in the lateral decubitus position on a peg board and draped in the usual sterile fashion for a posterior hip arthroplasty. A posterior approach through the prior surgical incision was utilized to minimize the risk of skin necrosis. Deep into the subcutaneous tissue, extensive fibrosis was encountered in the soft tissue and muscle due to the previous history. In addition, a large amount of sequestrum and femoral necrosis distal to the prefabricated spacer were visualized. The femoral fracture was traversing this region which had the appearance of being severely weakened by chronic infection. The original prefabricated spacer was removed successfully, followed by a thorough irrigation and debridement. The large region of necrotic bone and tissue present was radically resected several centimeters distal until viable bone was encountered. Neurolysis of the sciatic nerve was also performed due to fibrotic adhesions around the nerve.

Antibiotic spacer reimplantation

Because of these persistent signs of infection, reimplantation of Osteoremedy (The Remedy; OsteoRemedies, Memphis, TN) antibiotic spacer was deemed necessary. Due to the length of femur

resection, the standard Osteoremedy stem would have not been sufficient to span the defect and create a stable construct. To span this defect of the proximal to mid femur, we decided to utilize a 10-mm intramedullary nail (Advanced Orthopedic Solutions [AOS], Torrance, CA) as an endoskeleton secured to a prefabricated (The Remedy; OsteoRemedies, Memphis, TN) antibiotic-impregnated femoral head spacer (Fig. 2a). The remedy spacer is molded from antibiotic-impregnated cement, designed to allow for basic joint mobility, and releases antibiotics (4.8% gentamicin in sulfate) into the joint space to aid in prevention of bacterial colonization of the implant. Our intramedullary nail length was selected so as to bypass the femoral resection site by several cortical diameters to ensure proper fixation and prevent instability and risk of refracture. On the back table, a guidewire was driven through the proximal targeting module of the implant and into the femoral head with direct visualization of proper positioning of the femoral head spacer on the nail. In a similar fashion as a standard femoral nail for fracture, this would be done radiographically through a small incision. Following this, two 5.5-mm holes were drilled into the femoral head utilizing the proximal antegrade interlocking screw sheaths through the targeting guide in standard fashion. Next, 2 screws were inserted through the predrilled holes, passing through the intramedullary nail and ending just deep enough into the apex of the prefabricated femoral head (Fig. 3a). Next, the femoral canal was prepared using sequential reaming until a good bleeding bone was visualized, which in our case was with an 11.5-mm reamer. If necessary, after reaming, we also had the option of upsizing our nail diameter to 11 mm. The distal end of the nail-spacer device was inserted into the femoral canal. In order to properly customize the spacer and provide adequate soft-tissue tension and balance, we reduced the hip and pulled traction while visualizing our rod position. Once we confirmed that we had bypassed our femoral resection site by multiple cortical diameters, the intramedullary rod was removed and cut with large bolt cutters at the distal end to the proper length. The final nail-spacer device was then finally inserted to the previously determined depth, and the hip was again reduced (Fig. 2b). We then created an exoskeleton of antibiotic-loaded cement which circumferentially surrounded the intramedullary nail up until the point it entered the femoral canal

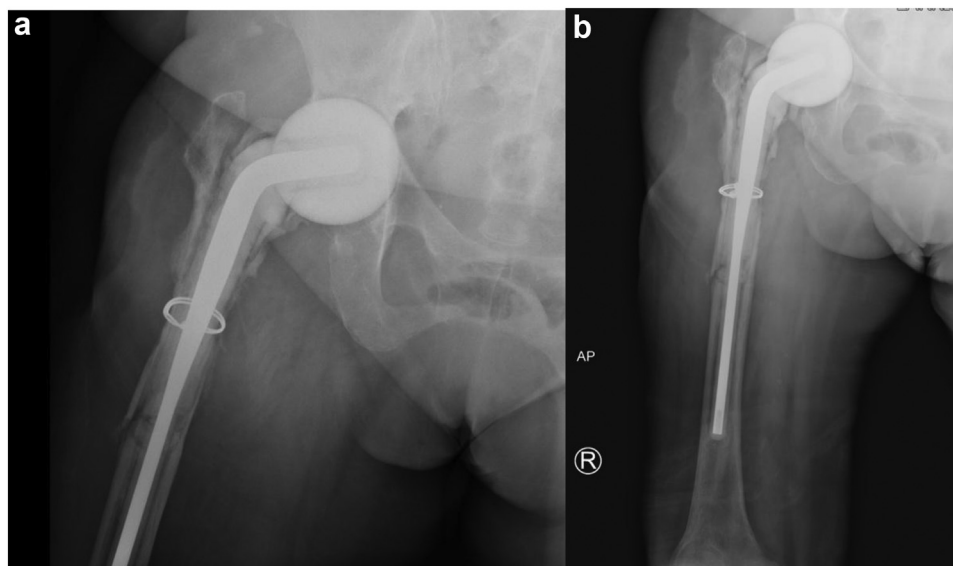


Figure 1. Pre operative imaging from patient's twisting trauma prior to custom spacer placement. (a) Preoperative anterior-posterior view of the right hip with the prefabricated hip spacer in place with sequestrum of proximal femur and a midshaft periprosthetic fracture. (b) Preoperative anterior-posterior view of the right femur with the prefabricated hip spacer in place, sequestrum of the right proximal femur, cerclage wire placement, and a periprosthetic midshaft femur fracture.

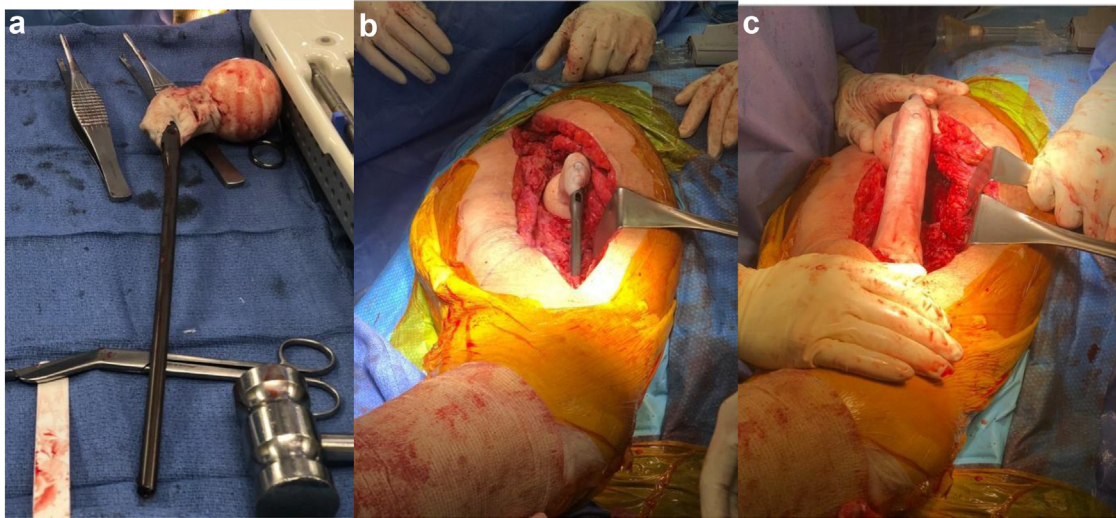


Figure 2. Intraoperative images of prefabricated spacer-nail device. (a) Intraoperative intramedullary rod fixation to prefabricated spacer head component. (b) Intraoperative provisional implantation of antibiotic spacer to assess length and fixation of the head component into the acetabulum. (c) Intraoperative final implantation of the spacer with distal insertion into the femur and proximal insertion into the acetabulum with surgeon-constructed antibiotic-loaded cement exoskeleton.

(Fig. 2c). A cerclage wire was added around the distal spacer-femoral interface to provide extra stability.

Antibiotic-loaded bone cement was used to secure the intramedullary nail interlocking screws to the prefabricated spacer head so as to simulate proper femoral neck offset. Four bags of vancomycin powder (1 g each) and 4 bags of tobramycin powder (1.2 g each) were mixed with polymethylmethacrylate Simplex bone cement (Stryker Orthopedics, Mahwah, NJ) and utilized to complete all final steps of cementation. Total antibiotic amount and specific antibiotics used in this step were based on the standard protocol at our facility and tailored specifically for this patient. This may need to be tailored differently based on each patient's comorbidity profile and the infectious organism determined on cultures. Following this, the wound was copiously irrigated and closed in a layered fashion.

Postoperative management

Partial weight-bearing status was maintained following surgery with standard posterior hip precautions for 6 weeks

consisting of not bending the operative hip past 90 degrees, maintaining seated posture at above 90 degrees, the use of a toilet seat lift, no bending over from a standing position, and no crossing legs over while sitting or lying down. An abduction pillow was used while sleeping for the first week postoperatively. Intravenous antibiotics were continued postoperatively for an additional 6 weeks. Postoperative radiographs were obtained to show proper fixation of the intramedullary rod into the distal femur and proper femoral head placement in the acetabulum (Fig. 3a and b). Repeat aspiration 2 months later demonstrated successful eradication of the infection. The patient went on to spacer removal uneventfully via the same initial approach and second-stage reimplantation utilizing revision multihole acetabular cup components and a proximal femoral replacement system (Fig. 4a and b).

Discussion

Various studies have discussed treatment of failed articulating antibiotic spacers; however, due to the heterogeneity in bone loss,

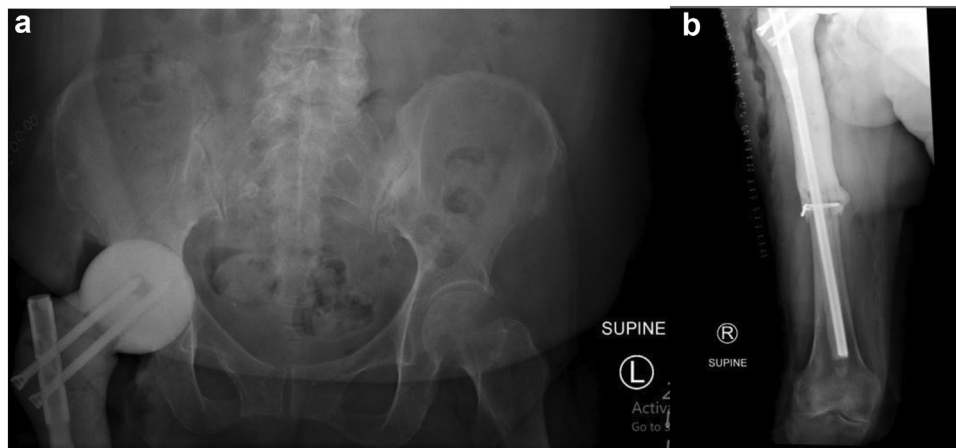


Figure 3. Postoperative radiographs after antibiotic spacer insertion. (a) Postoperative anterior-posterior view of the pelvis demonstrates the prefabricated spacer head with screw fixation to the intramedullary nail in anatomic position in the acetabulum. (b) Postoperative anterior-posterior view of the femur demonstrates intramedullary nail fixation into the midshaft and distal femur, cerclage wire fixation, and antibiotic-impregnated cement surrounding the nail.

available implants, surgeon technique, and patient-specific factors, different surgical techniques must be utilized to create an appropriate construct. This paper details a method for constructing an antibiotic cement spacer in the setting of extensive bone loss in the femur. Our prefabricated nail-spacer construct allows for complete control of femoral neck offset and, thus, soft-tissue tensioning, which is different from the nail-spacer combo that is currently manufactured by OsteoRemedies.

Sancineto et al. presented a small study in 2018 showing preliminary outcomes using proximal femur mega-spacers similar to ours [16]. They did not use a prefabricated OsteoRemedy antibiotic spacer as a femoral head. They instead took 2 doses of antibiotic cement, each dose containing 1 g of tobramycin, 1 g of vancomycin, 2 g of imipenem, and 1 g of colistin, and filled up the bulb of a Bonneau's syringe. Prior to the cement completely setting, they drilled 2 small holes using Schanz screws. Instead of inserting their nail as one unit, they sat the cement head into the acetabulum, inserted the intramedullary device into the femoral canal, then joined the 2 using cephalic screws through the greater trochanter [16]. This type of technique would not have been feasible in our case due to the level of proximal femur bone loss. Sanz-Ruiz et al. provided another outlook of a technique with similar principles as ours using a biarticular cement spacer for infected total hip and knee arthroplasty which had massive bone loss [17]. Focusing on the hip, their technique used the same principles as mentioned above to create a femoral head using a bulb syringe [17]. They did, however, note that it worked better to invert the bulb prior to cement casting to avoid creating an uneven surface with crests as seen in the study by Sancineto et al. [16]. Procedural steps similar to our technique were used for the remainder of the implants to assemble the prosthesis by inserting cephalic screws through a gamma nail that was completely coated with antibiotic cement. Another case series published by Shields et al. showed the use of a pseudoacetabular component that could be created with antibiotic cement, and then combined with a proximal femur antibiotic spacer in cases of severe bone loss [18]. Their proximal femur preparation included the use of an intramedullary nail that was attached to a 100-mm cephalomedullary lag screw and then

locked in position with a set screw prior to implantation [18]. Similar to our technique, they use antibiotic cement to outline the portion of the nail that was not placed into the intramedullary canal. The difference with this technique is that their femoral head was formed by hand, with the size template being a hemiarthroplasty sizing guide. The cement was then allowed to dry, and the femoral component was reduced to articulate with the formed pseudoacetabulum [18].

Minimizing the number of spacer exchanges while treating PJI is optimal to maintain range of motion and prevent bone loss, even when utilizing articulating spacers [19]. However, when femoral fracture or significant infection of surrounding bone does occur, radical resection should be considered to minimize the risk for future revision or exchange surgery. Initial exchange of the antibiotic spacer for a similar implant in our patient did not result in clearance of the infection and also did not adequately prevent the patient from sustaining a femoral fracture following spacer exchange. In this case, a radical resection along with the usage of a robust intramedullary implant allowed for proper clearance of the infection, while also providing adequate mechanical strength until reimplantation.

Although periprosthetic infection eradication rates appear to be similar between surgeon-made antibiotic spacers and preformed commercially available antibiotic spacers [20,21], it is worth noting that we were able to combine these techniques to provide an increased local concentration of antibiotics. In addition to the low-dose antibiotic-impregnated prefabricated spacer, we also utilized a surgeon-made antibiotic-impregnated exoskeleton resembling the femoral shaft. This provided us the ability to secure the intramedullary nail in position at the appropriate depth as well as theoretically increase local antibiotic concentrations and synergy, commonly described as “passive opportunism” [22].

Care must be taken to avoid systemic antibiotic toxicity when utilizing a combined spacer as in this case. It has been recommended to include at least 3.6 g of tobramycin and 1 g of vancomycin in each 40-g bag of bone cement during spacer formation to reach effective antibiotic elution levels. Additionally, it is possible to introduce as much as 10–12 g of antibiotics

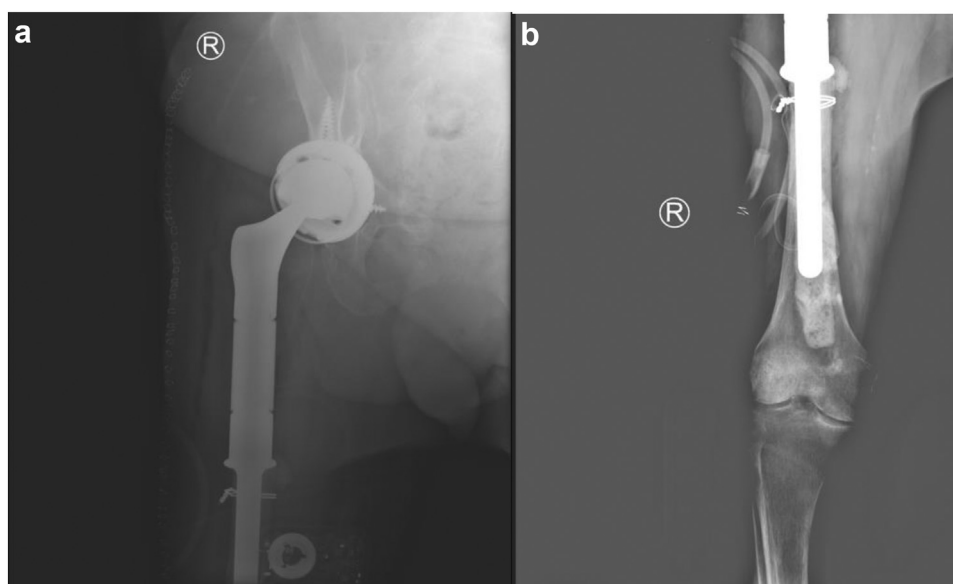


Figure 4. Final postoperative radiographs after proximal femur replacement. (a) Eight-week postoperative anterior-posterior definitive fixation of right hip radiograph demonstrating proximal femur replacement with multihole acetabular-constrained component. (b) Eight-week postoperative anterior-posterior definitive fixation of right femur radiograph demonstrating the distal aspect of proximal femur replacement with cerclage wiring and cement mantle within the distal femur.

in 1 bag of bone cement, but >4.5 g of antibiotics per bag of bone cement will decrease the mechanical properties of a standard prosthesis [23]. Although there is no consensus as to the optimal range for antibiotic-loaded bone cement in spacers, several case reports suggesting a dose-dependent risk of acute kidney injury (AKI) from surgeon-made antibiotic spacers utilizing aminoglycosides have been described [24,25]. In a study by Menge et al. [25], the odds ratio of developing AKI among patients receiving a spacer containing more than 4.0 g of vancomycin was 5.97 (95% confidence interval, 1.33–26.72; $P = .02$), and 5.87 for those receiving a spacer containing more than 4.8 g of tobramycin (95% confidence interval, 1.43–24.19; $P = .01$), compared with patients receiving antibiotic doses below these levels. They did note that nearly 90% of their patients had comorbidities such as hypertension, diabetes, cardiovascular disease, congestive heart failure, vascular disease and rheumatoid arthritis, and/or other renal pathology which could have predisposed them to a higher risk of AKI. Further studies should be undertaken to elucidate the safety profile and optimal doses of antibiotics, especially when combining prefabricated spacers with surgeon-made spacers.

Interestingly, although the posterior approach was utilized throughout this patient's treatment course, no spacer dislocation was seen throughout the multiple spacer exchange procedures performed. We believe that using the largest implant possible with an increased head-neck ratio maintains soft-tissue tension, along with proper alignment of the spacer components. Due to the various nail sizes available, we were able to adjust the length of the intramedullary implant to maximize soft-tissue tensioning while also maintaining a secure distal femoral diaphyseal fit. The ease of combining an intramedullary implant with a preformed spacer also minimized the time needed for construction of what would have been a rather cumbersome surgeon-made antibiotic spacer without sacrificing modularity. A study by Incavo et al. utilizing custom-made antibiotic spacers with an endoskeleton of spinal fixation rods to treat periprosthetic hip infection reported a low dislocation rate of 1 of 12 patients (9%) but required a rather extensive preparation of these components intraoperatively [26]. In our case, we were able to quickly combine implants intraoperatively while still controlling femoral neck-shaft angle and rotation, as well as hip offset.

Overall, there is a paucity of literature discussing the treatment of significant femoral loss or fracture in chronic periprosthetic hip infection. A few studies, including ours, have described specific techniques used to span femoral defects, but these are typically surgeon- and institution-specific. In the future, multicenter collaboration will likely be necessary to better assess the techniques available for treating large bony defects. These experiences can further guide implant companies in the development of antibiotic-impregnated spacers that can address bony and soft-tissue deficiencies while eradicating infection. Although these prefabricated implants can be costly, they can improve efficiency and value-based care by decreasing overall surgical times and avoiding return to the operating theater due to complications seen with surgeon-constructed antibiotic spacers.

Summary

Articulating antibiotic-impregnated spacers continues to be a valuable option in treating chronic periprosthetic infection while maintaining long-term patient functionality. We report on a specific technique that can be utilized to address bony deficiency at the time of revision surgery. It is our hope that this technique, among others, can serve to inform joint reconstructive surgeons on the current options available to effectively treat complications surrounding the use of articulating spacers for periprosthetic infection.

Conflicts of interest

A. Corces receives royalties from Arthrex for knee design. For full disclosure statements refer to <https://doi.org/10.1016/j.artd.2022.03.013>.

Informed patient consent

The author(s) confirm that informed consent has been obtained from the involved patient(s) or if appropriate from the parent, guardian, power of attorney of the involved patient(s); and, they have given approval for this information to be published in this article.

References

- Lieberman JR, Callaway GH, Salvati EA, Pellicci PM, Brause BD. Treatment of the infected total hip arthroplasty with a two-stage reimplantation protocol. *Clin Orthop* 1994;301:205–12.
- Toulson C, Walcott-Sapp S, Hur J, et al. Treatment of infected total hip arthroplasty with a 2-stage reimplantation protocol: update on "our institution's" experience from 1989 to 2003. *J Arthroplasty* 2009;24:1051–60.
- Fehring TK, Odum S, Calton TF, Mason JB. Articulating versus static spacers in revision total knee arthroplasty for sepsis. The Ranawat Award. *Clin Orthop* 2000;380:9–16.
- Emerson RH, Muncie M, Tarbox TR, Higgins LL. Comparison of a static with a mobile spacer in total knee infection. *Clin Orthop* 2002;404:132–8.
- Baleani M, Traina F, Toni A. The mechanical behaviour of a pre-formed hip spacer. *HIP Int* 2003;13:159–62.
- Kummer FJ, Strauss E, Wright K, Kubiak EN, Di Cesare PE. Mechanical evaluation of unipolar hip spacer constructs. *Am J Orthop Belle Mead NJ* 2008;37:517–8.
- Hofmann AA, Kane KR, Tkach TK, Plaster RL, Camargo MP. Treatment of infected total knee arthroplasty using an articulating spacer. *Clin Orthop* 1995;45–54.
- Rastogi D, Dwivedi MK. Hand-made articulating cement spacers in two-stage revision for infected total hip arthroplasty: a prospective cohort study. *Orthop Proc* 2019;101-B(Suppl_4):3.
- Ha C-W. A technique for intraoperative construction of antibiotic spacers. *Clin Orthop* 2006;445:204–9.
- Biring GS, Kostamo T, Garbus DS, Masri BA, Duncan CP. Two-stage revision arthroplasty of the hip for infection using an interim articulated Prostalac hip spacer: a 10- to 15-year follow-up study. *J Bone Joint Surg Br* 2009;91:1431–7.
- Goltzer O, McLaren A, Overstreet D, Galli C, McLemore R. Antimicrobial release from prefabricated spacers is variable and the dose is low. *Clin Orthop* 2015;473:2253–61.
- Maupin JJ, Corning E, Steinmetz RG, White J. Creating a dual articulating antibiotic spacer for management of an infected total femur prosthesis hemiarthroplasty. *Arthroplast Today* 2019;5:482–5. <https://doi.org/10.1016/j.artd.2019.07.002>.
- Jung J, Schmid NV, Kelm J, Schmitt E, Anagnostakos K. Complications after spacer implantation in the treatment of hip joint infections. *Int J Med Sci* 2009;6:265–73.
- Anagnostakos K, Jung J, Schmid NV, Schmitt E, Kelm J. Mechanical complications and reconstruction strategies at the site of hip spacer implantation. *Int J Med Sci* 2009;6:274–9.
- Success of two-stage reimplantation in patients requiring an interim spacer exchange - the journal of arthroplasty. [https://www.arthroplastyjournal.org/article/S0883-5403\(18\)30296-1/fulltext](https://www.arthroplastyjournal.org/article/S0883-5403(18)30296-1/fulltext) [accessed 15.01.21].
- Sancineto CF, Pereira Duarte M, Garcia Mansilla I, Taype Zamboni DR, Carabelli GS, Barla JD. Preliminary outcomes of proximal femur megaspacers. *Arthroplasty Today* 2019;5:164–71. <https://doi.org/10.1016/j.artd.2018.09.008>.
- Sanz-Ruiz P, Matas-Diez JA, Villanueva-Martinez M, Carbo-Laso E, Lopez-Torres II, Vaquero-Martín J. A new biarticular cement spacer technique for infected total hip and knee arthroplasty with massive bone loss. *HIP Int* 2019;31:242–9. <https://doi.org/10.1177/1120700019884557>.
- Shields D, Kong R, Gupta S, Mahendra A. A novel antibiotic spacer for significant proximal femoral loss - surgical technique. *Open Orthopaedics J* 2017;11:508–16. <https://doi.org/10.2174/1874325001711010508>.
- Rava A, Bruzzone M, Cottino U, Enrietti E, Rossi R. Hip spacers in two-stage revision for periprosthetic joint infection: a review of literature. *Joints* 2019;7:56–63.
- D'Angelo F, Negri L, Zatti G, Grassi FA. Two-stage revision surgery to treat an infected hip implant. A comparison between a custom-made spacer and a pre-formed one. *Chir Organi Mov* 2005;90:271–9.

- [21] D'Angelo F, Negri L, Binda T, Zatti G, Cherubino P. The use of a preformed spacer in two-stage revision of infected hip arthroplasties. *Musculoskelet Surg* 2011;95:115–20.
- [22] Penner MJ, Masri BA, Duncan CP. Elution characteristics of vancomycin and tobramycin combined in acrylic bone-cement. *J Arthroplasty* 1996;11: 939–44.
- [23] Hanssen AD, Spangehl MJ. Practical applications of antibiotic-loaded bone cement for treatment of infected joint replacements. *Clin Orthop* 2004;427:79–85.
- [24] Patel RA, Baker HP, Smith SB. Acute renal failure due to a tobramycin and vancomycin spacer in revision two-Stage knee arthroplasty. *Case Rep Nephrol* 2018;2018:6579894.
- [25] Menge TJ, Koethe JR, Jenkins CA, et al. Acute kidney injury after placement of an antibiotic-impregnated cement spacer during revision total knee arthroplasty. *J Arthroplasty* 2012;27:1221.e1–2.
- [26] Incavo SJ, Russell RD, Mathis KB, Adams H. Initial results of managing severe bone loss in infected total joint arthroplasty using customized articulating spacers. *J Arthroplasty* 2009;24:607–13.